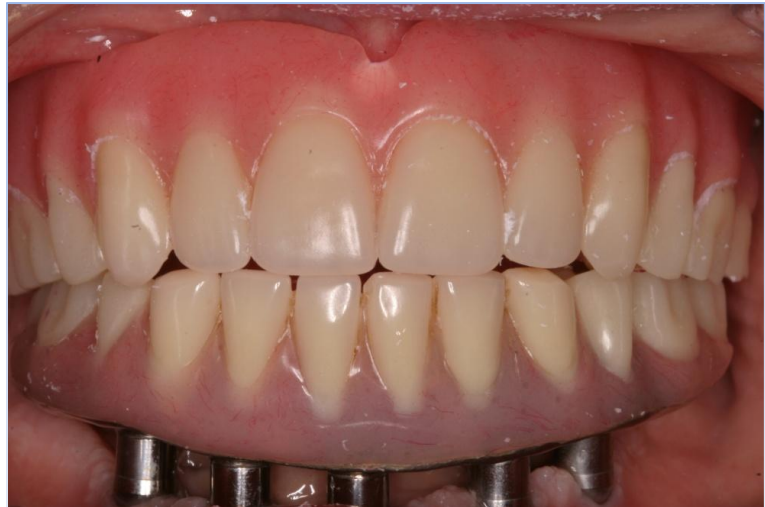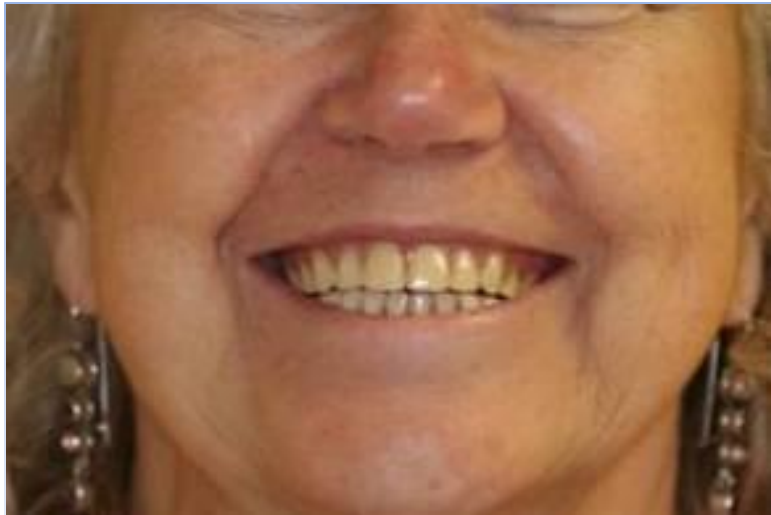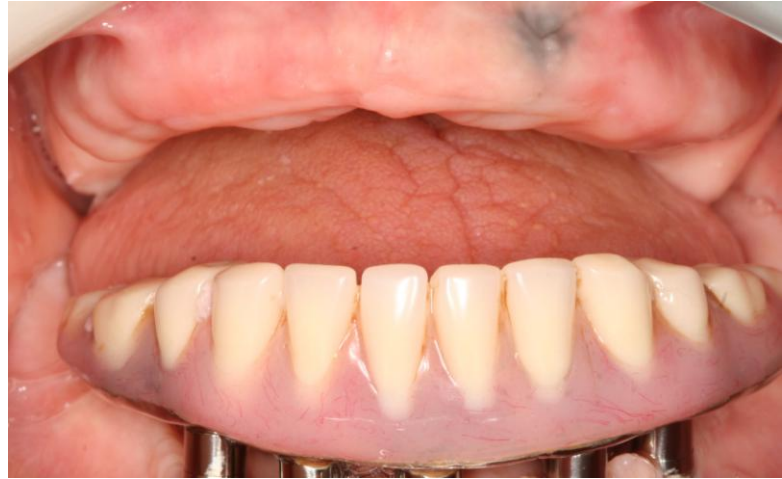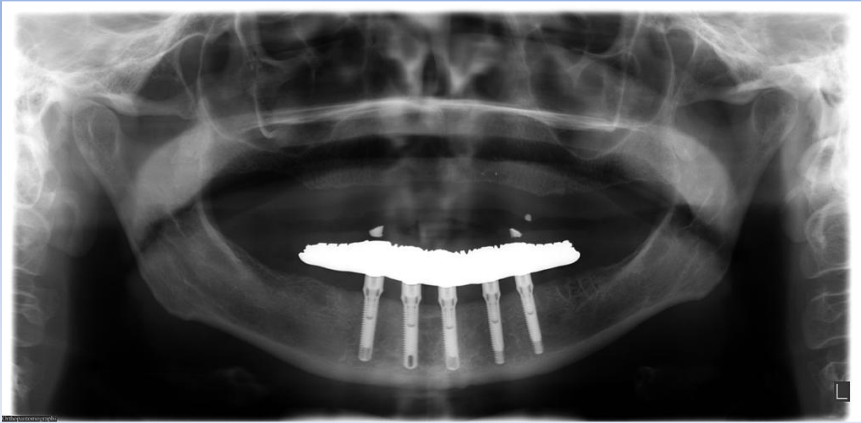


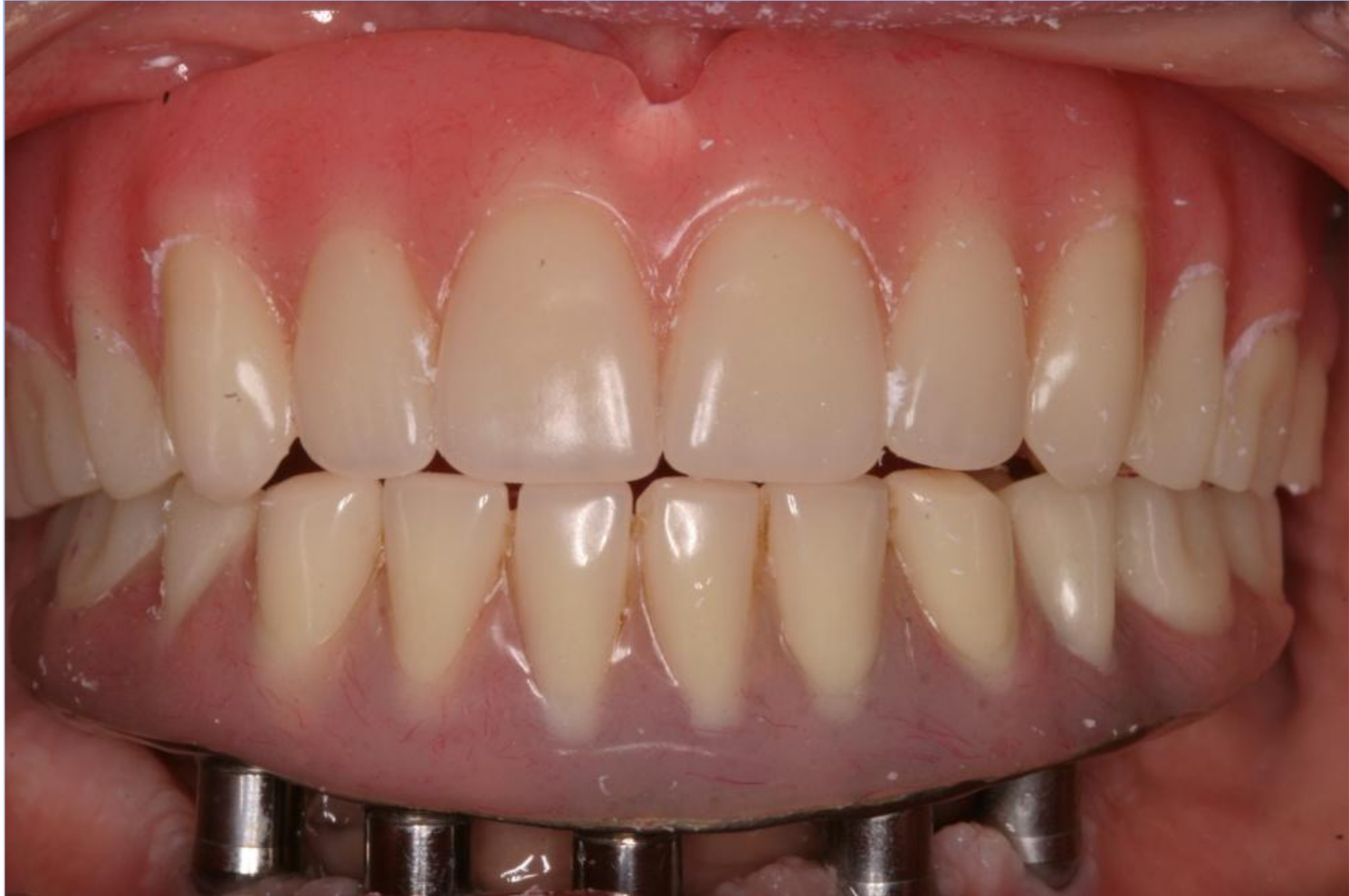# Zimmer® Revitalize™ Patient Solutions Case Presentation

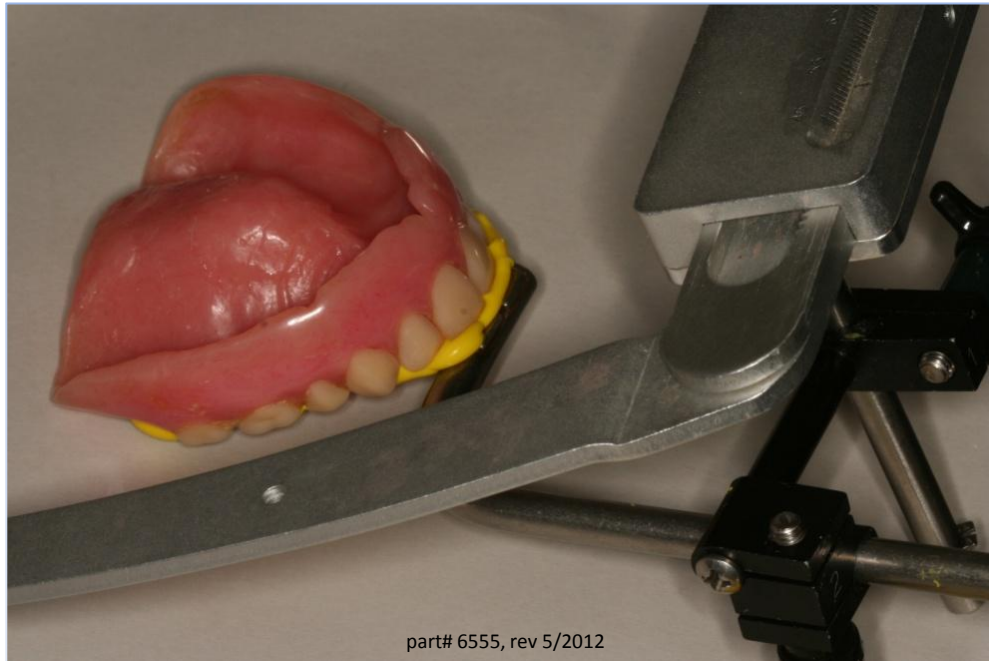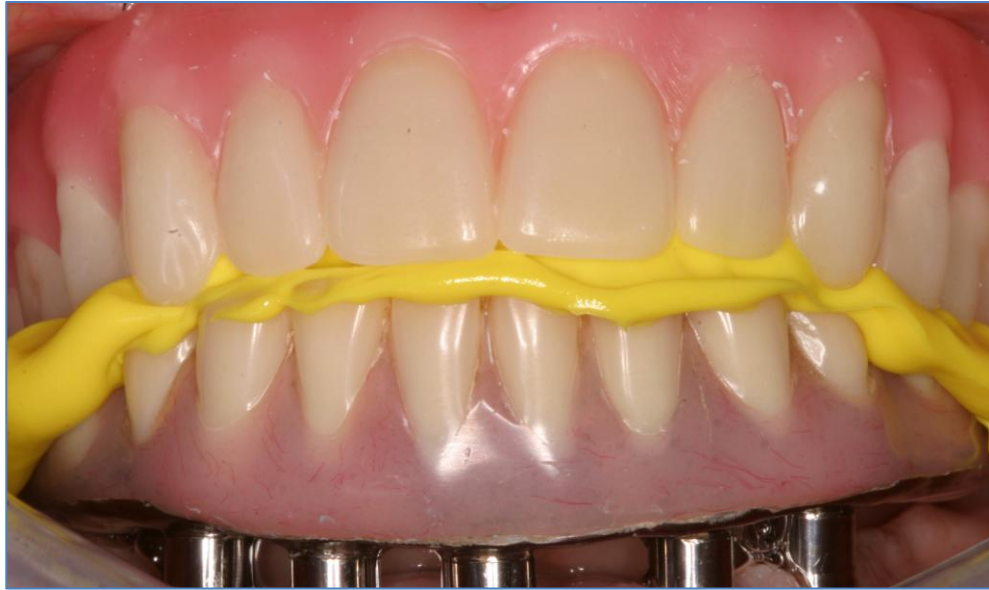Photos courtesy of:

Dr. Edwin McGlumphy, DDS, MS

Dr. Peter Larsen, DDS

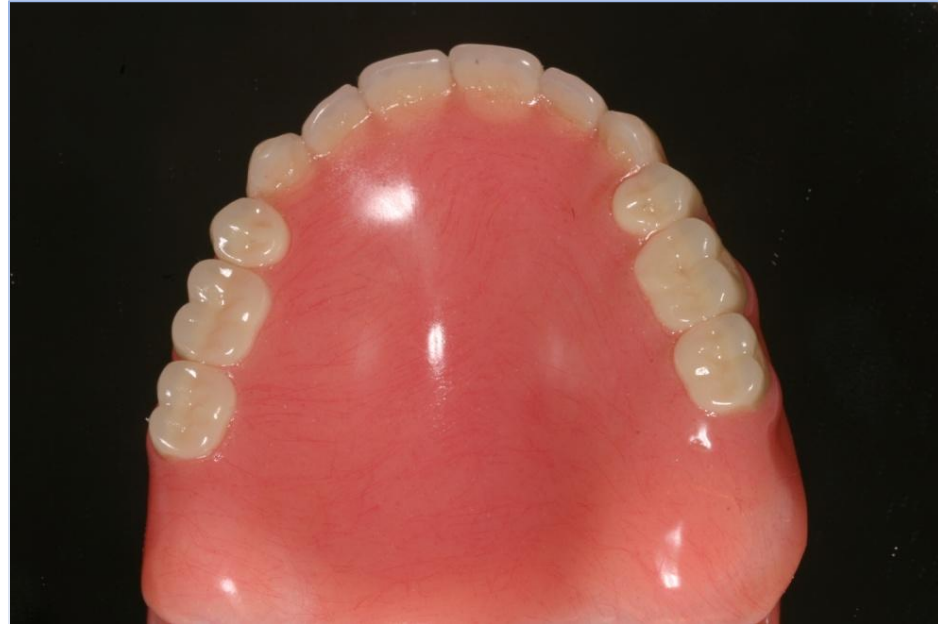
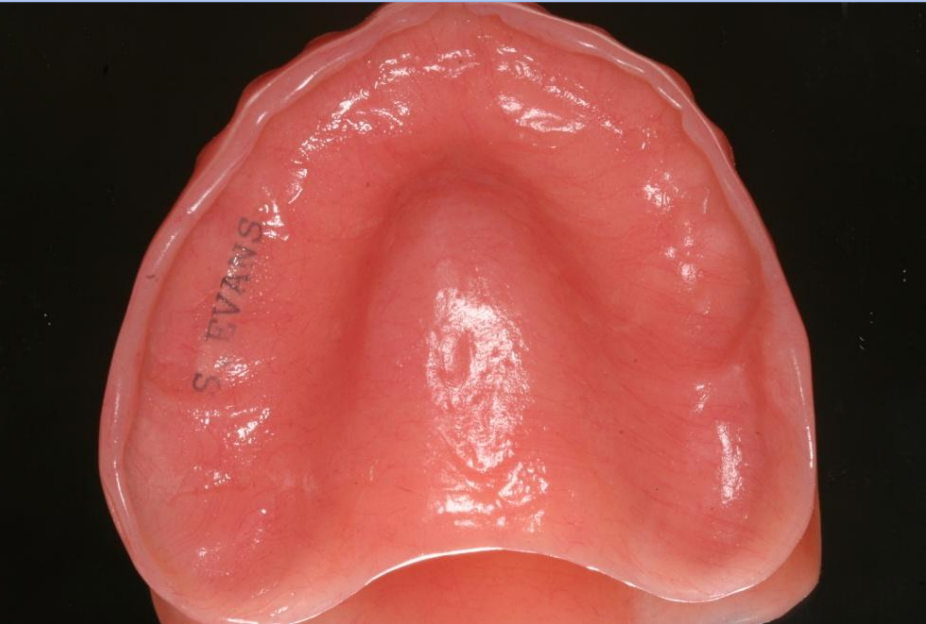
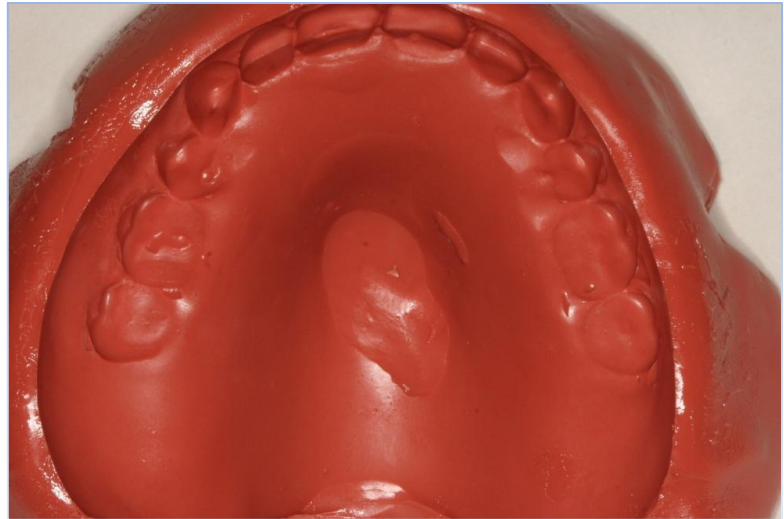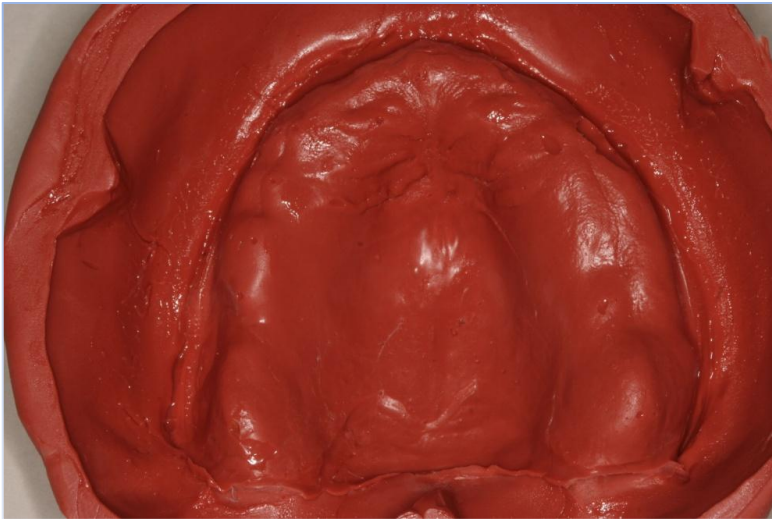


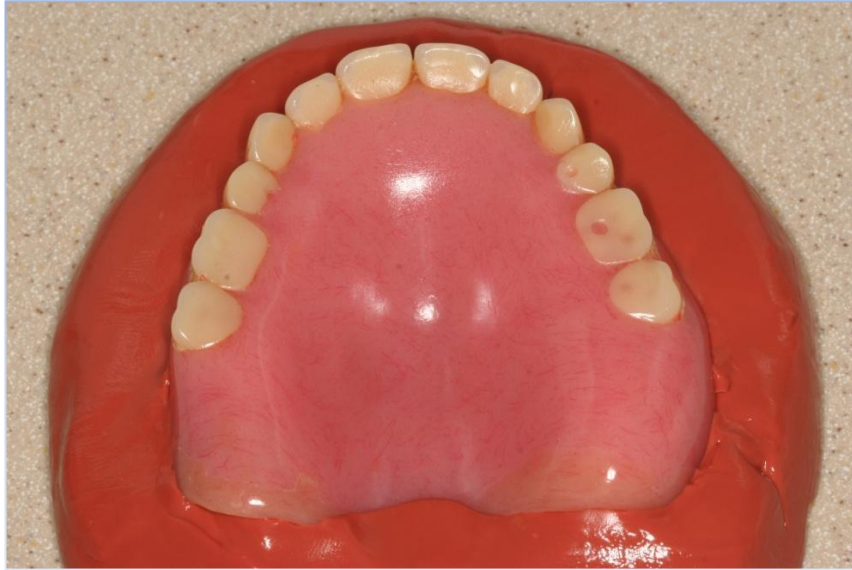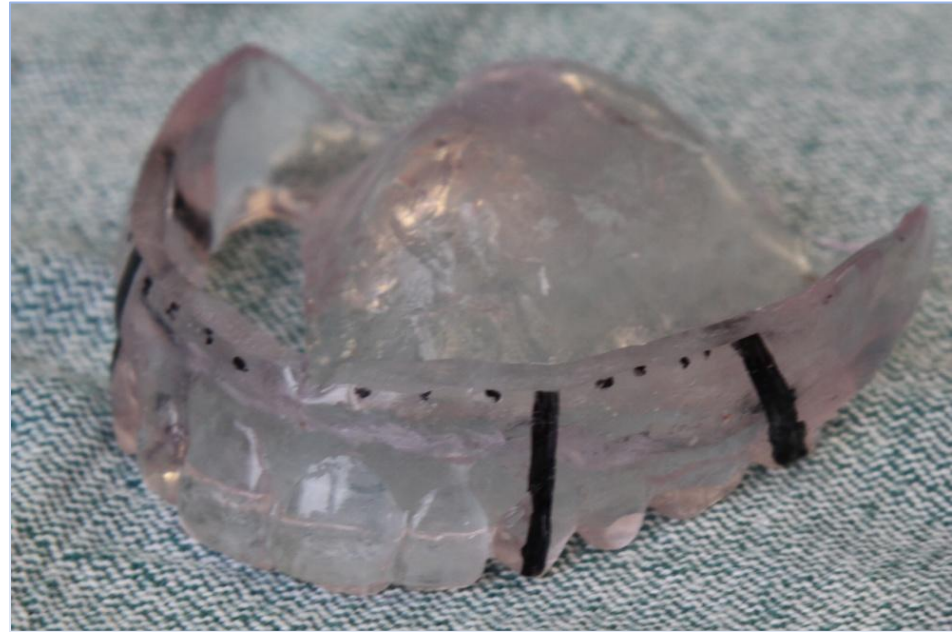
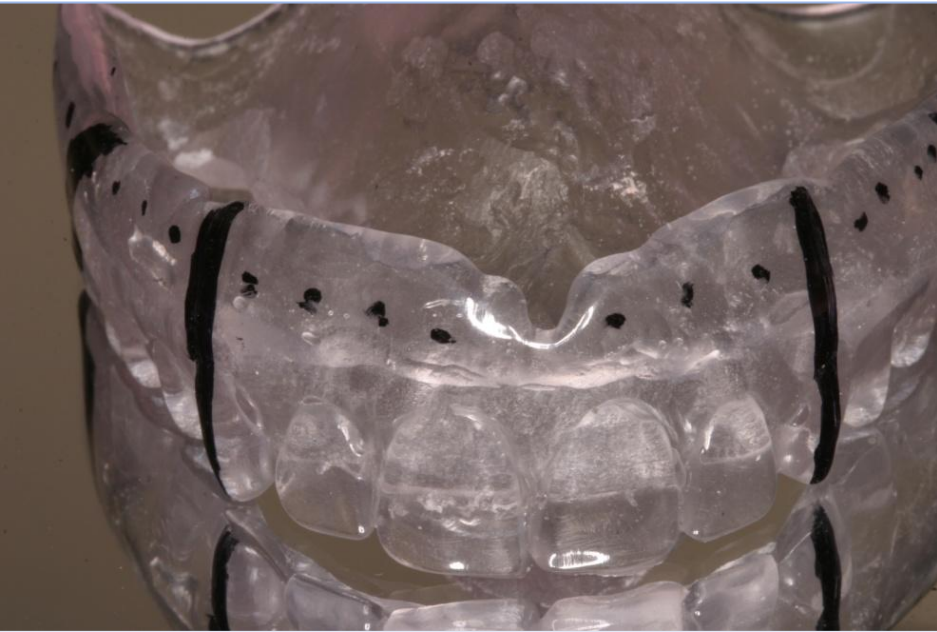


part# 6555, rev 5/2012


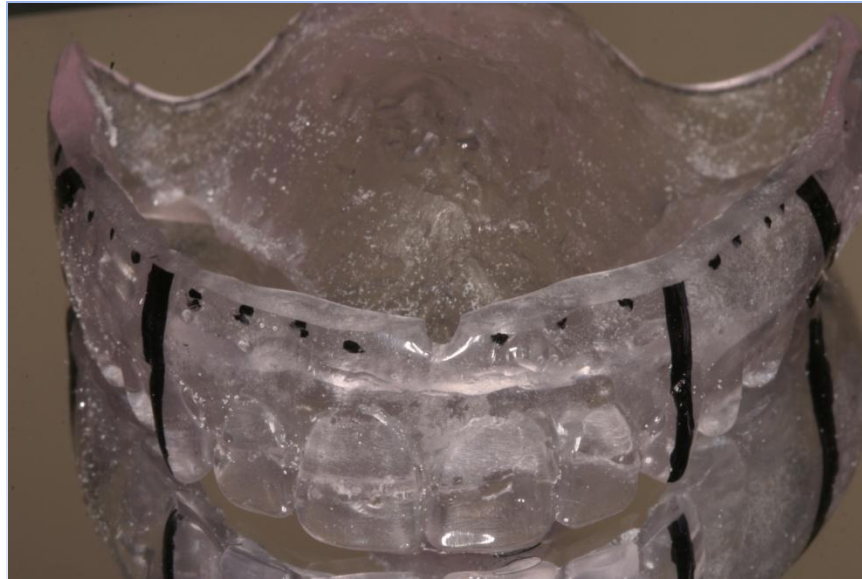



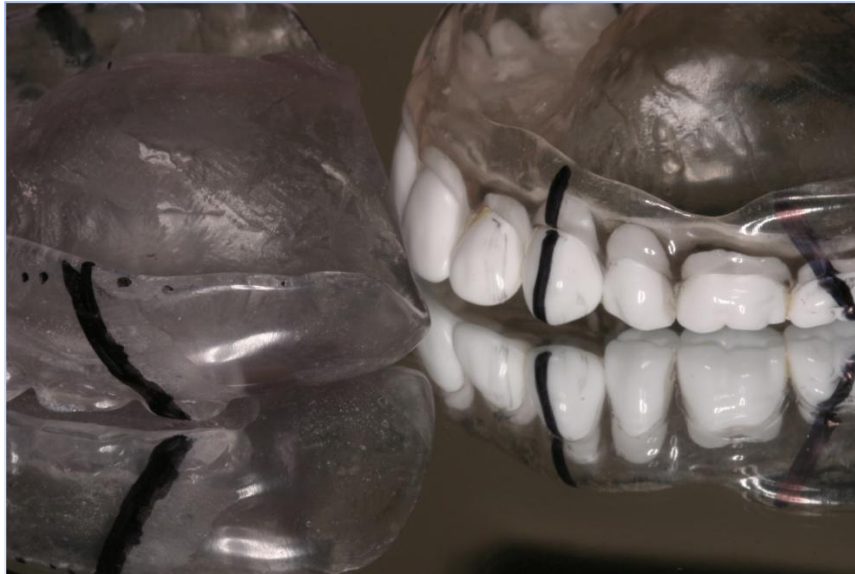
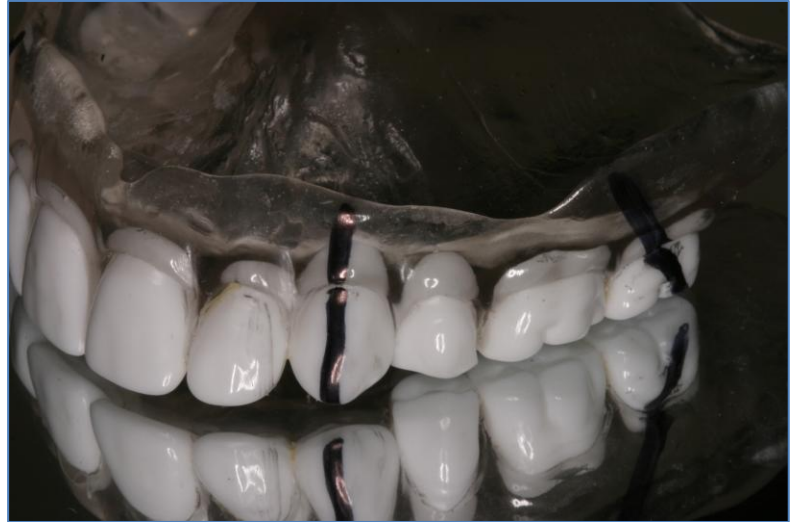
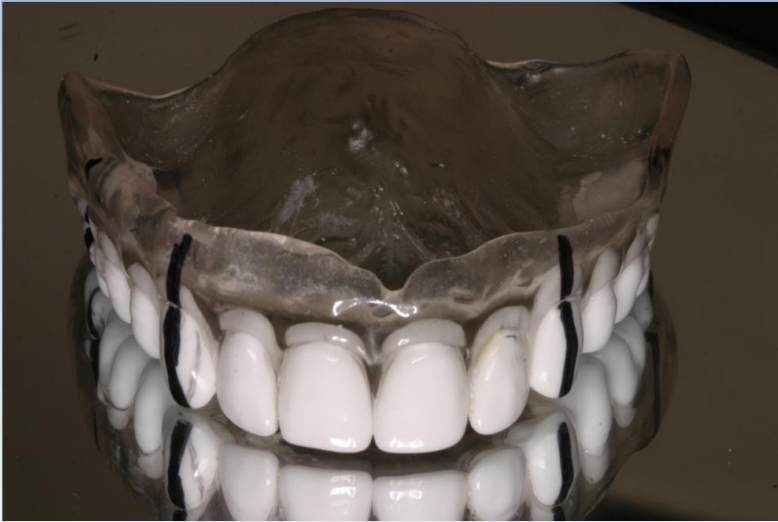
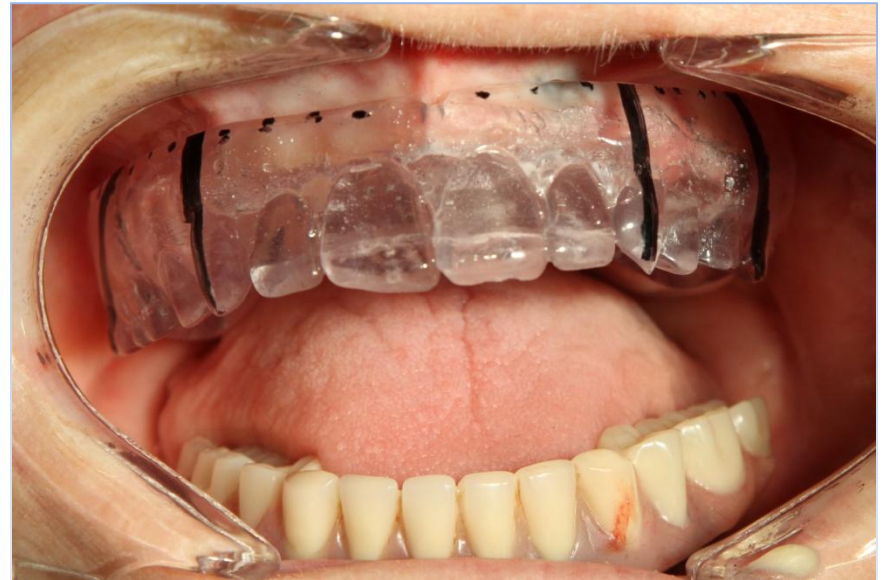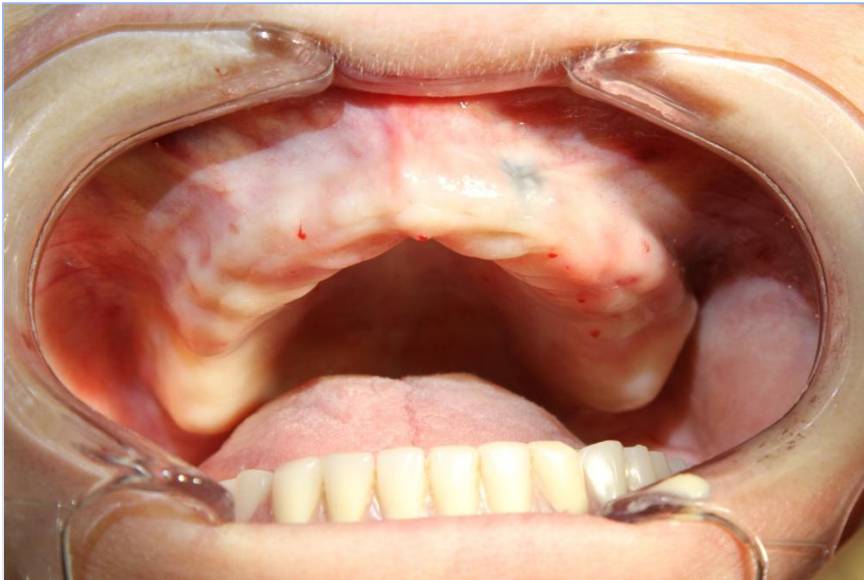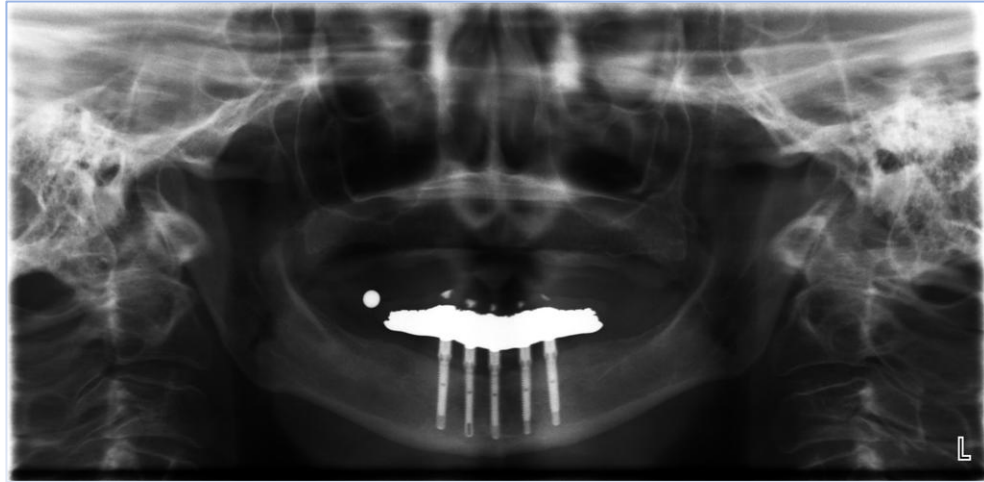


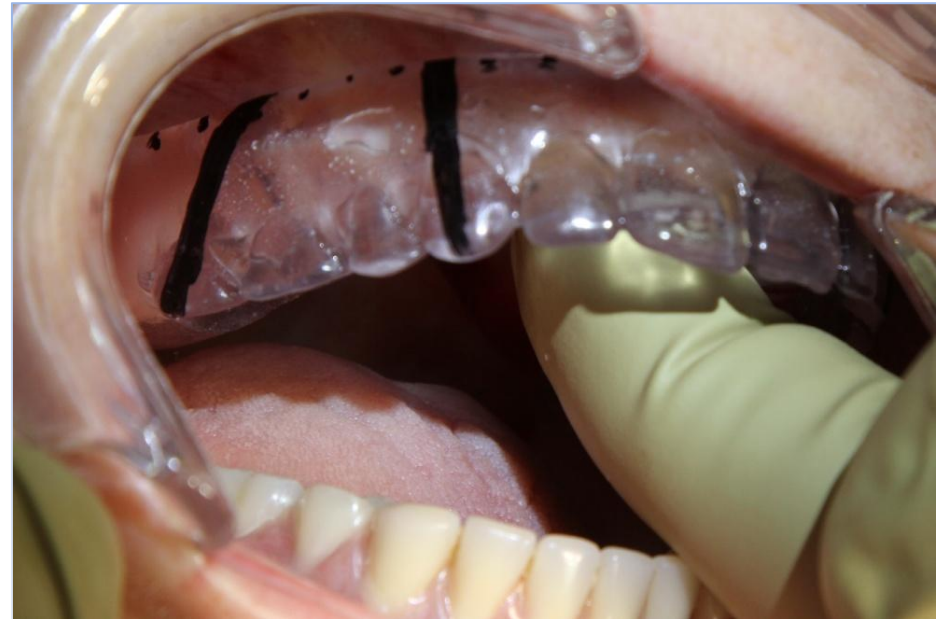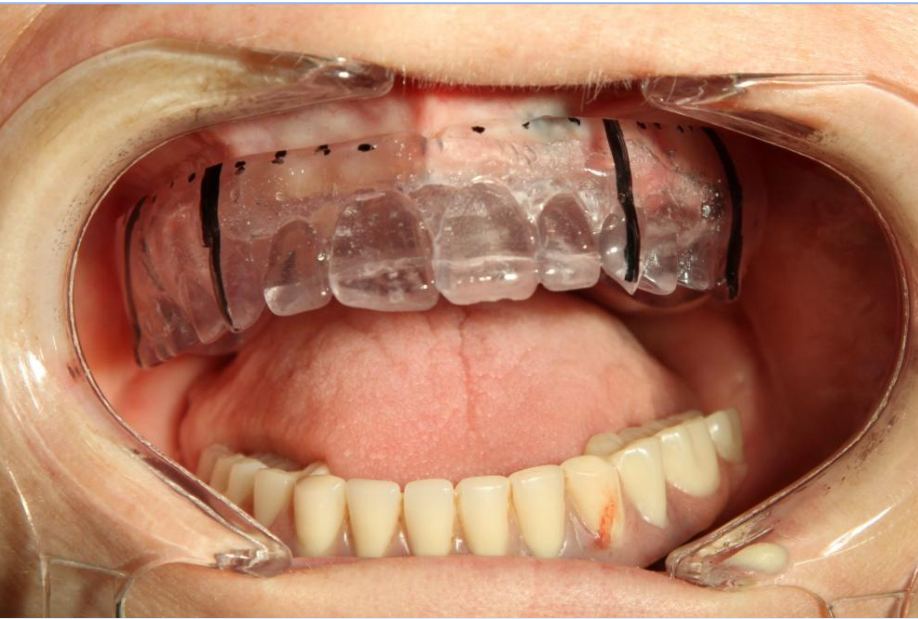




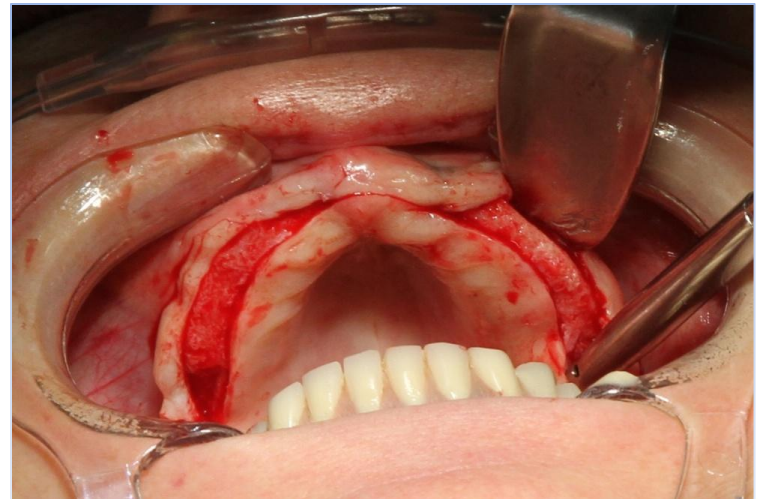



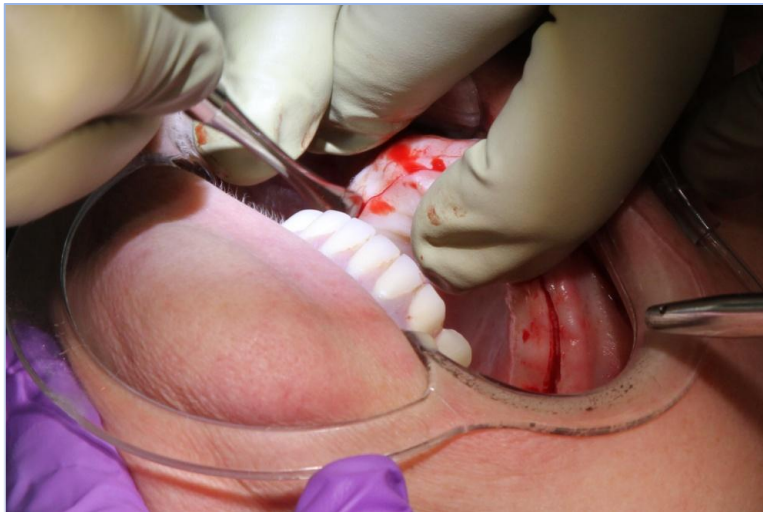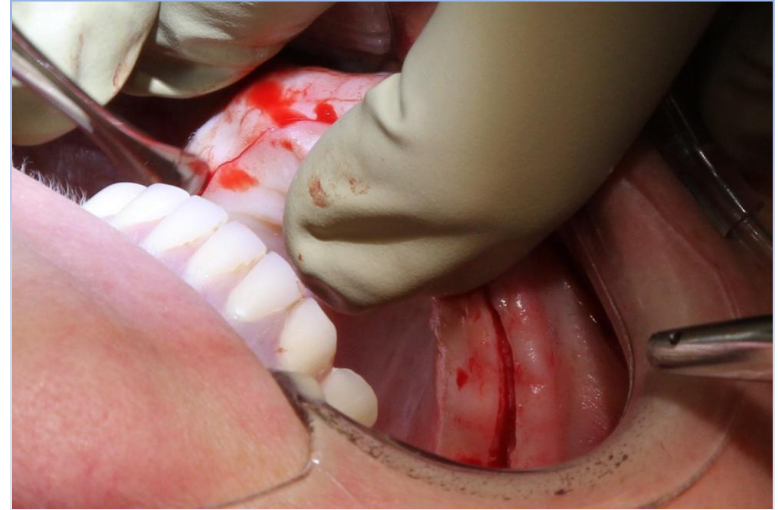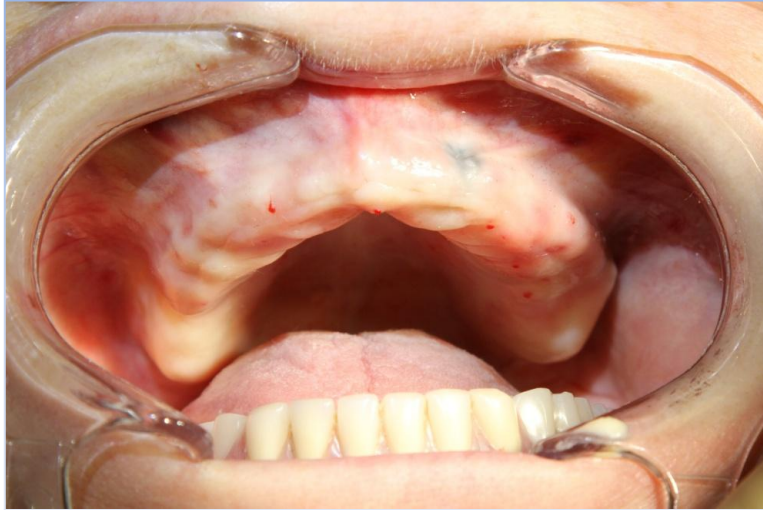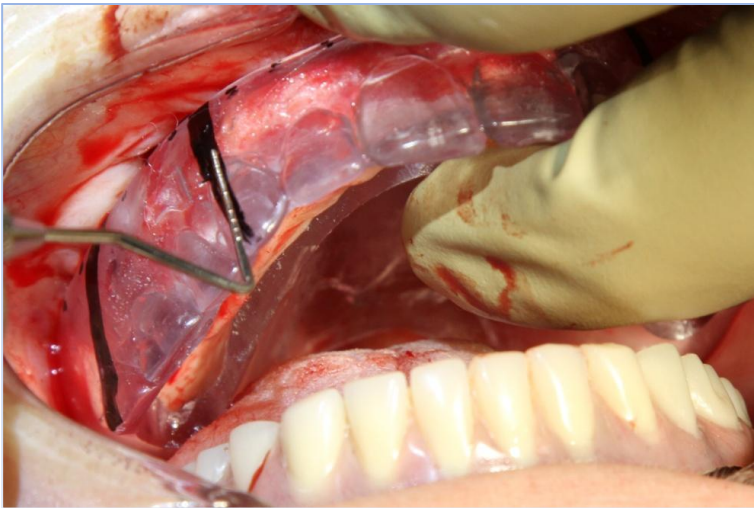
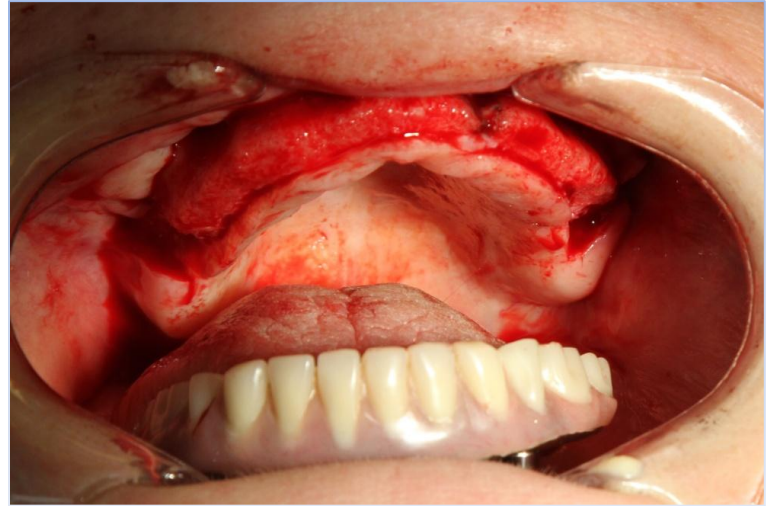
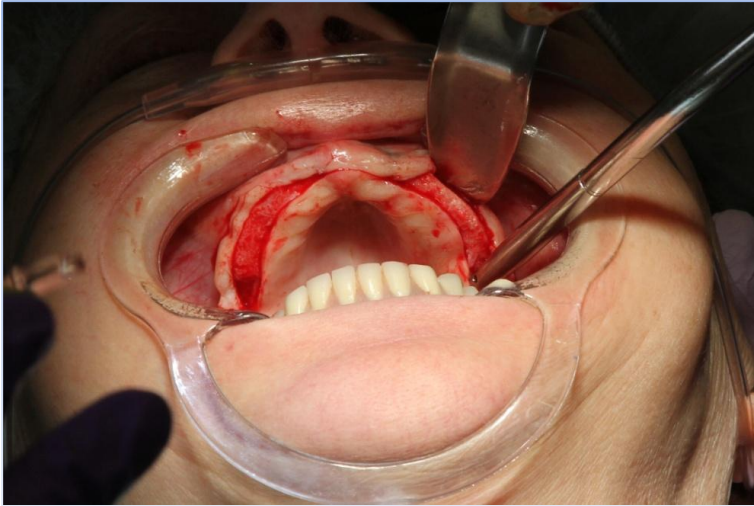




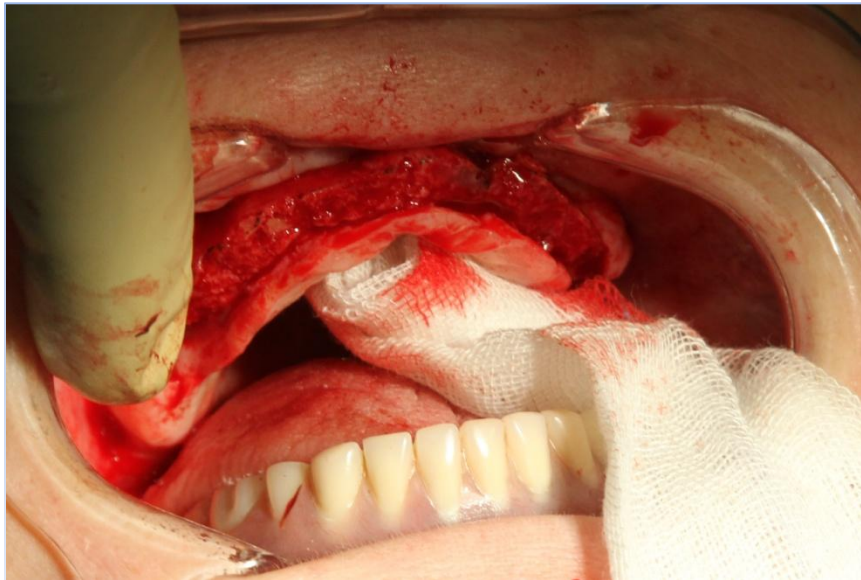
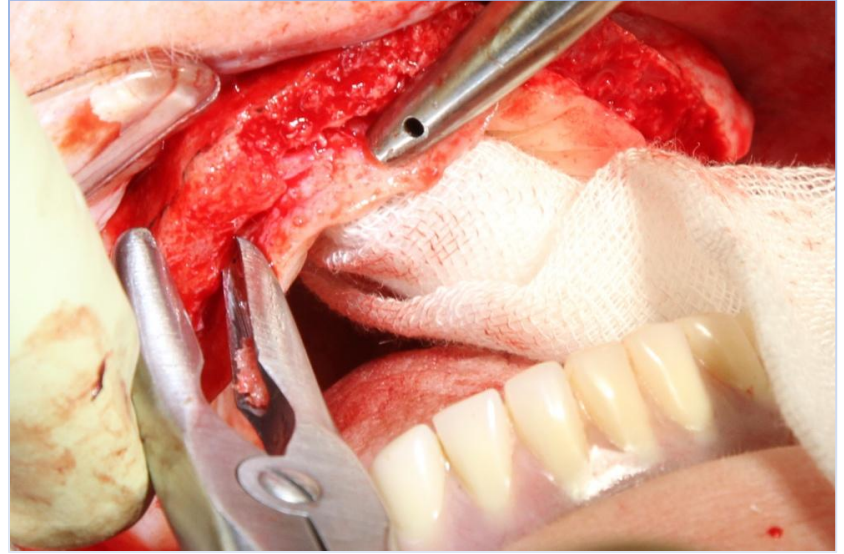
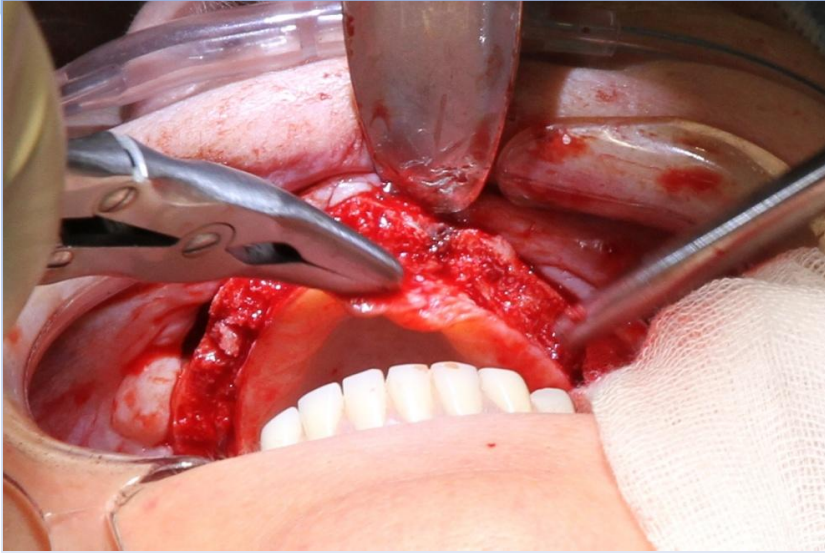








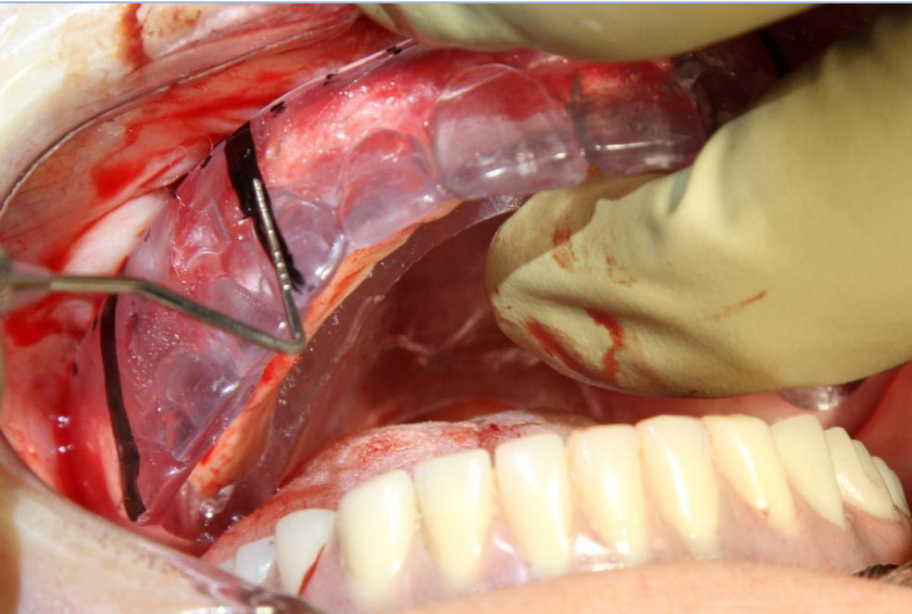




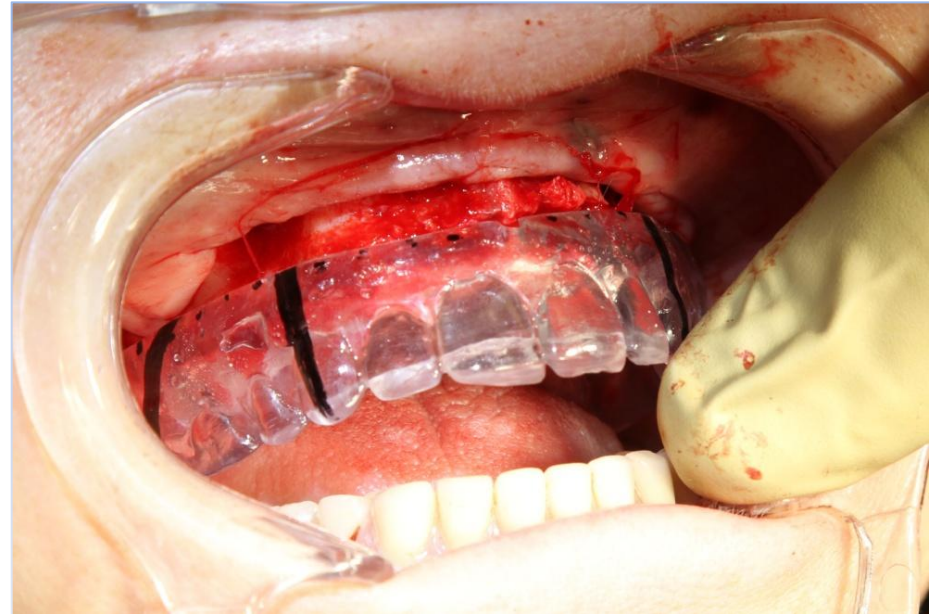
part# 6555, rev 5/2012

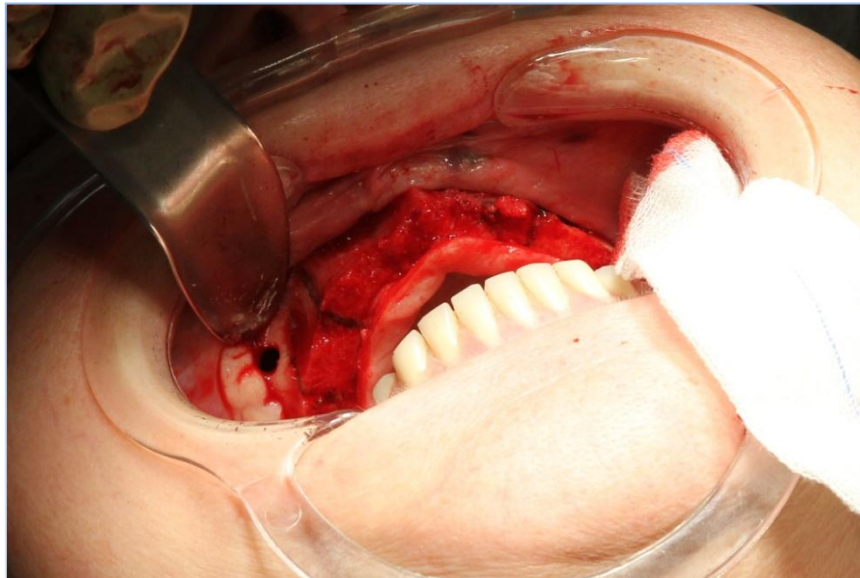
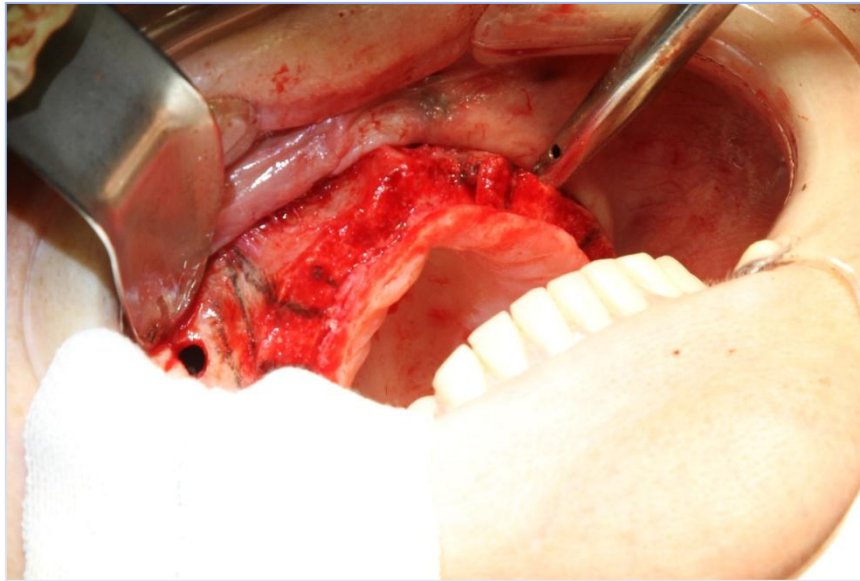


Before bone reduction

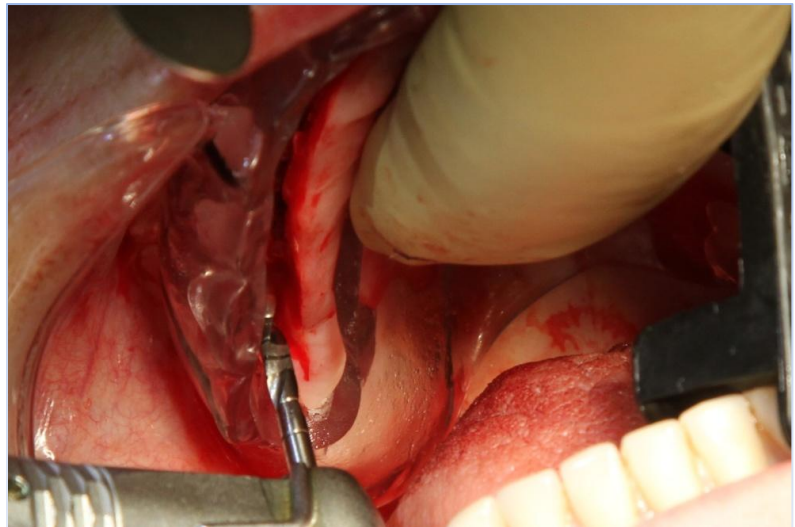
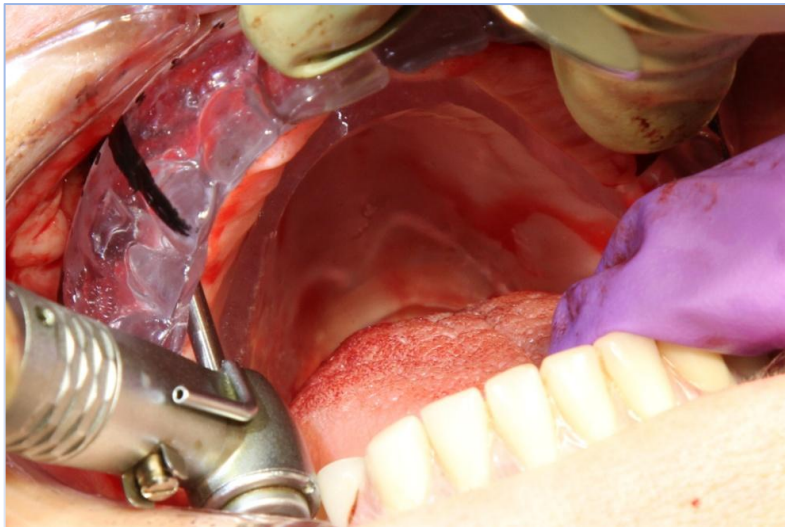
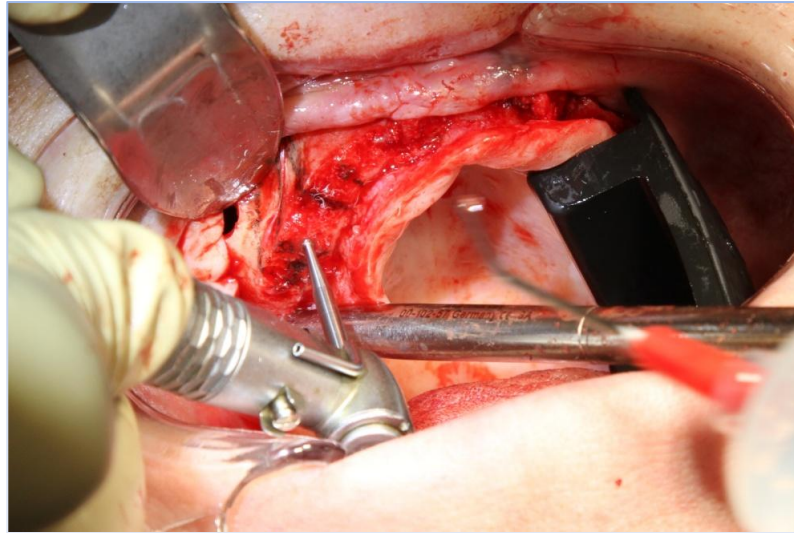


After bone reduction

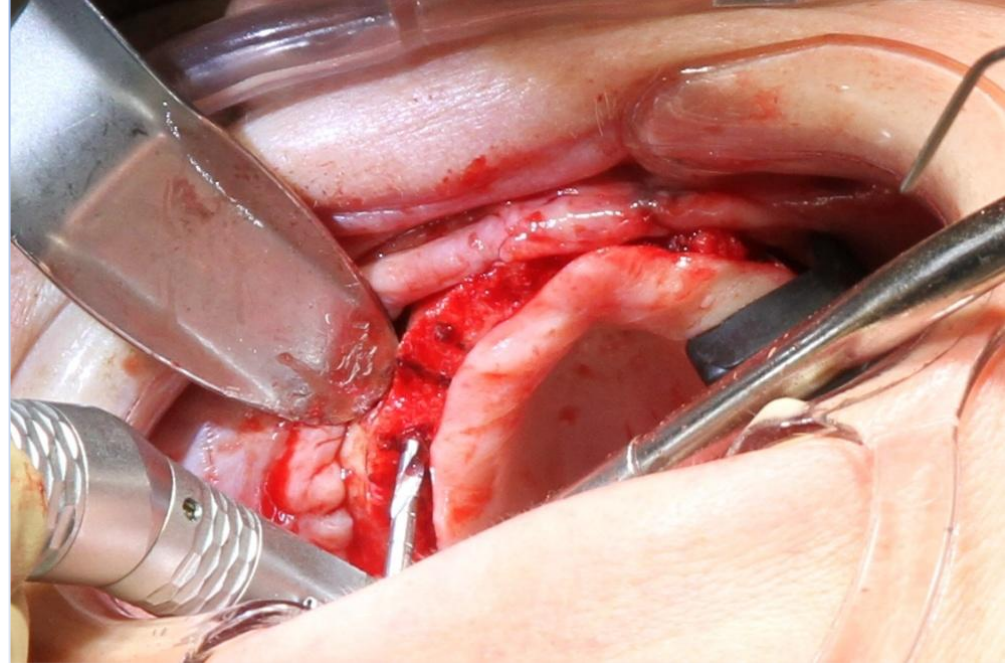
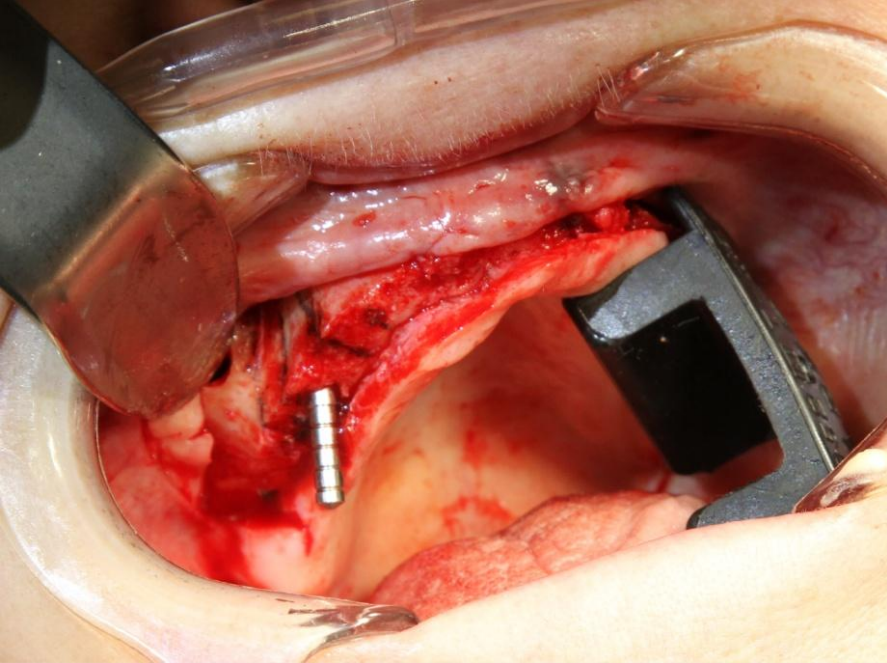


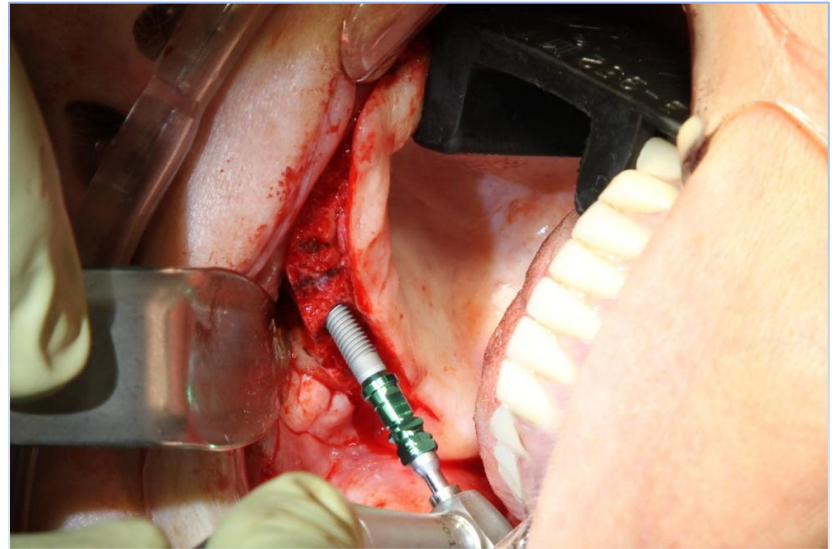
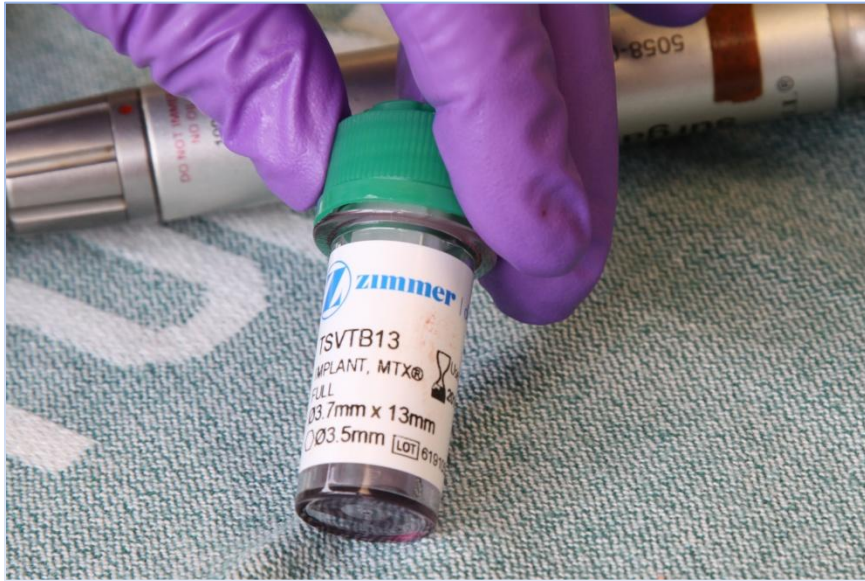




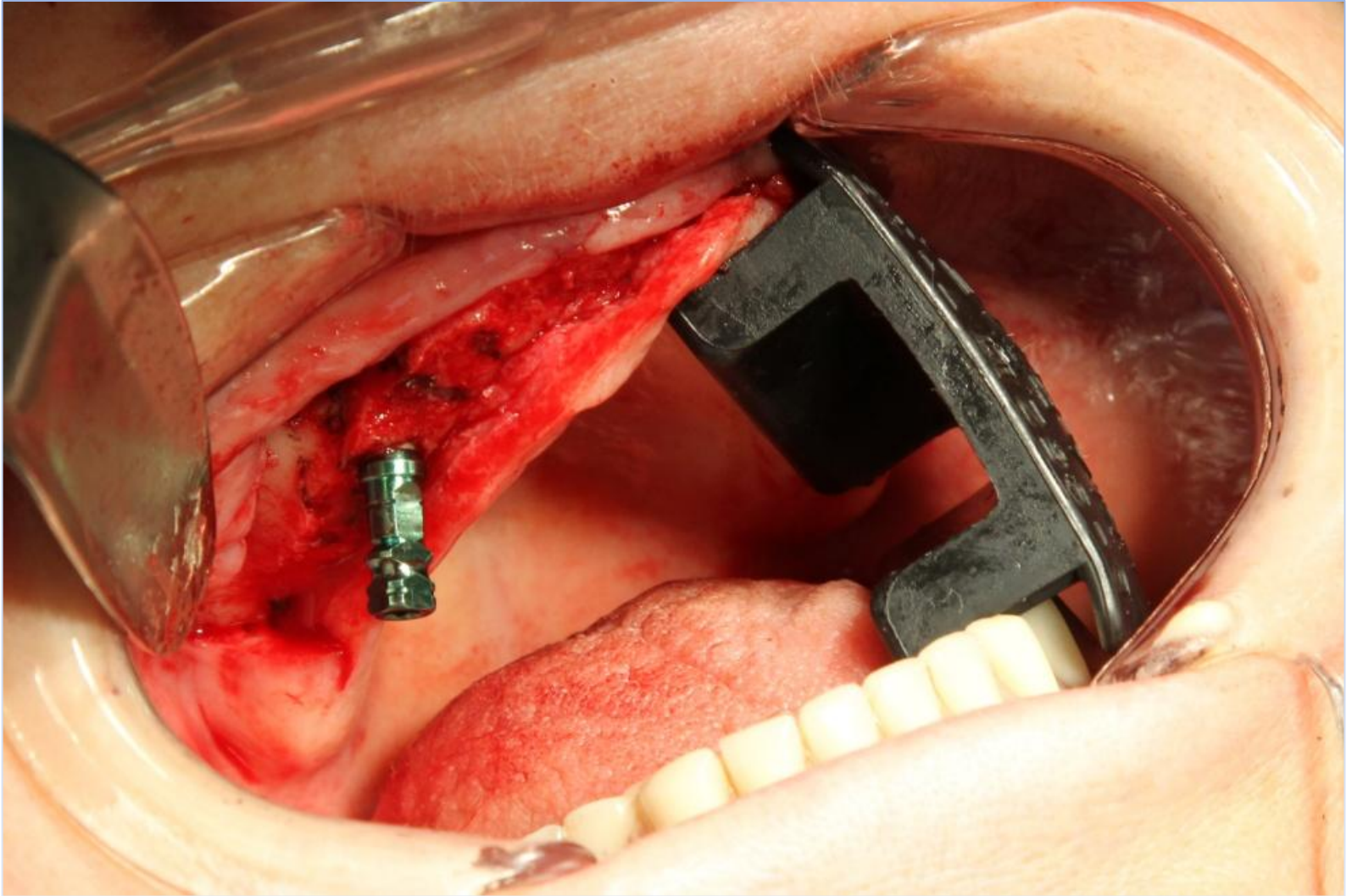




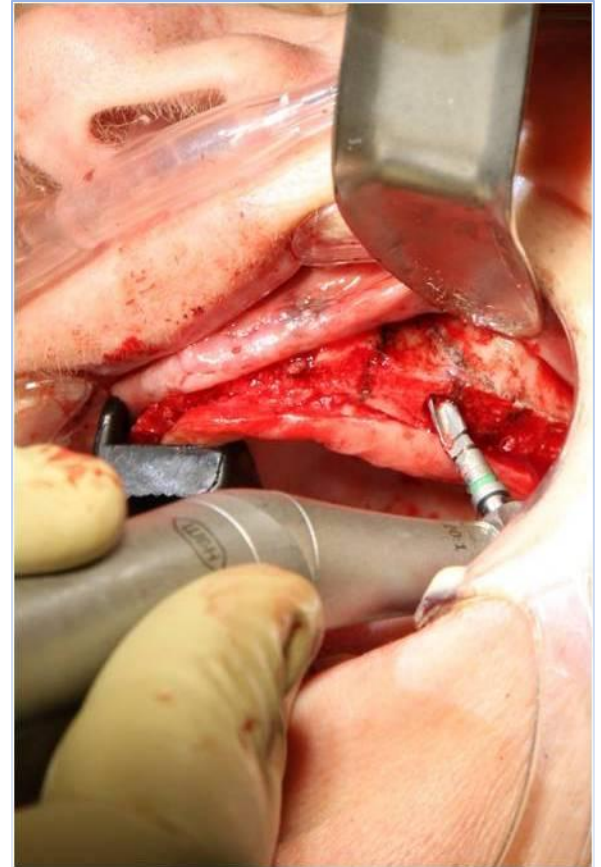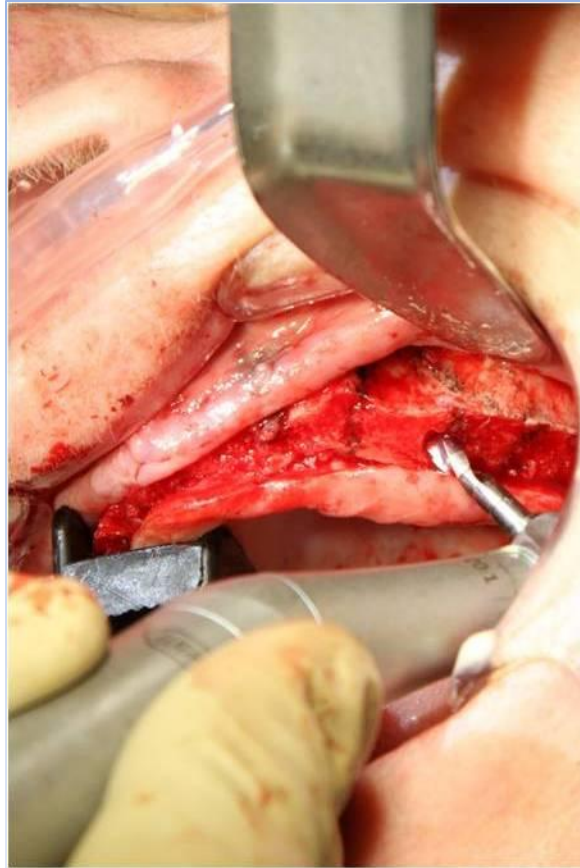
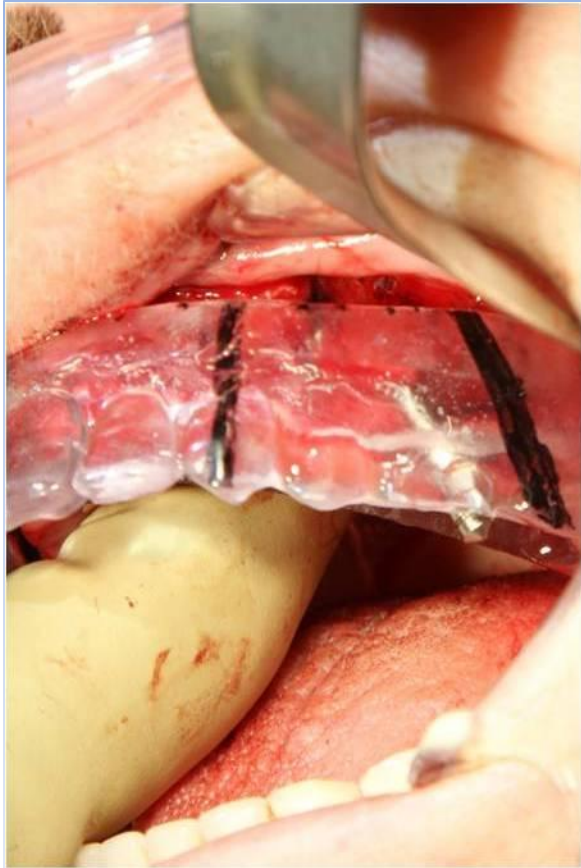


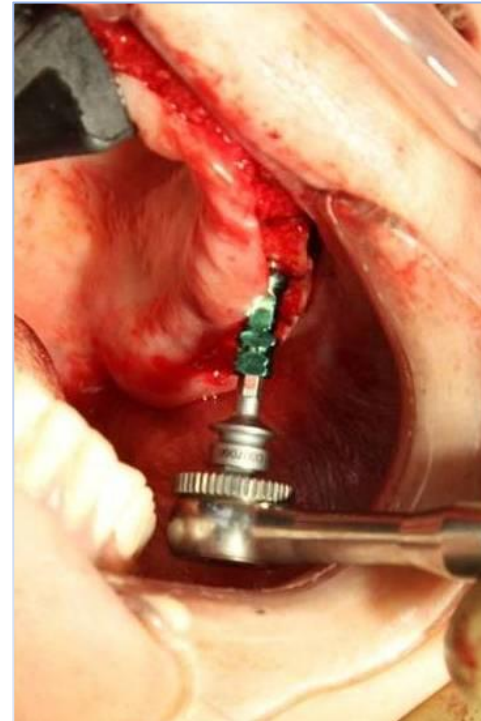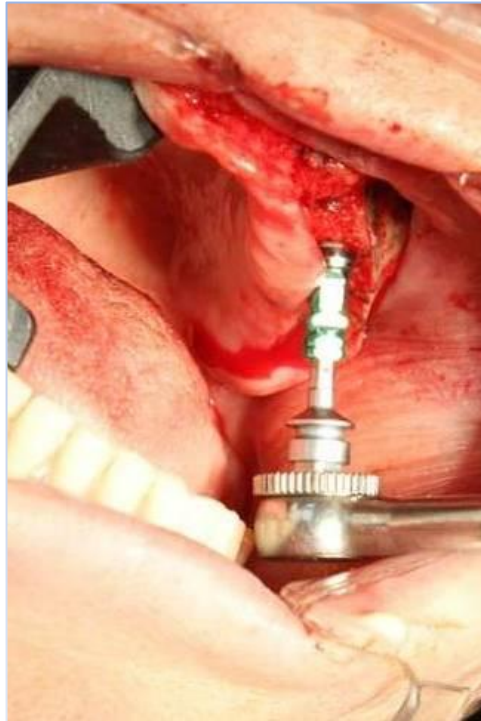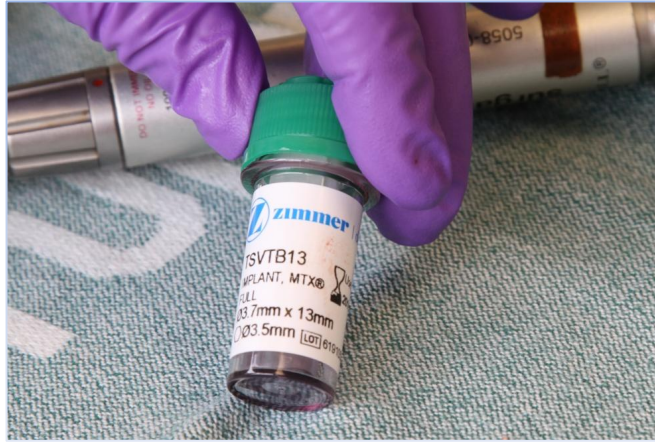




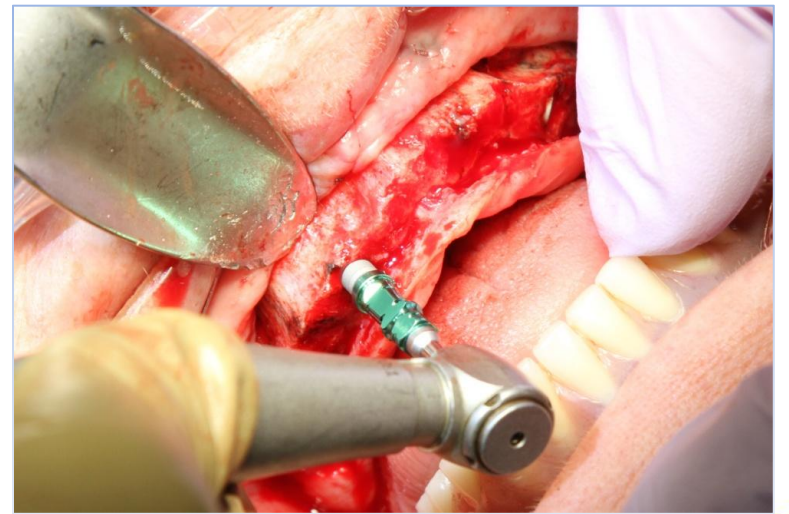
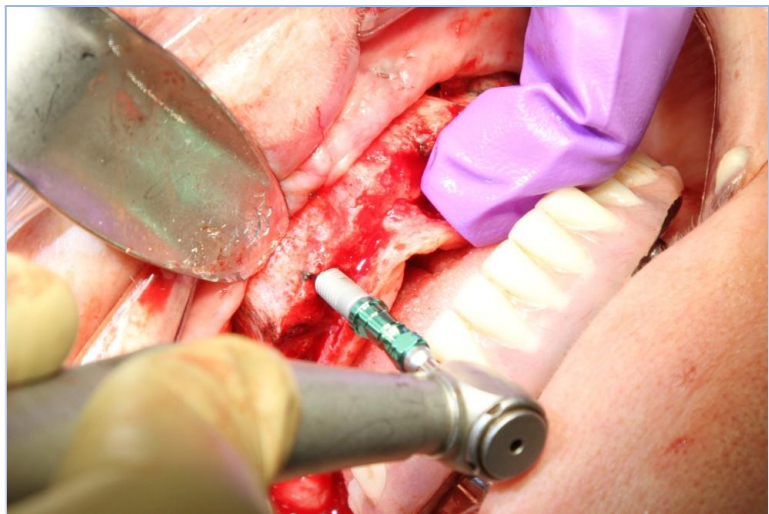
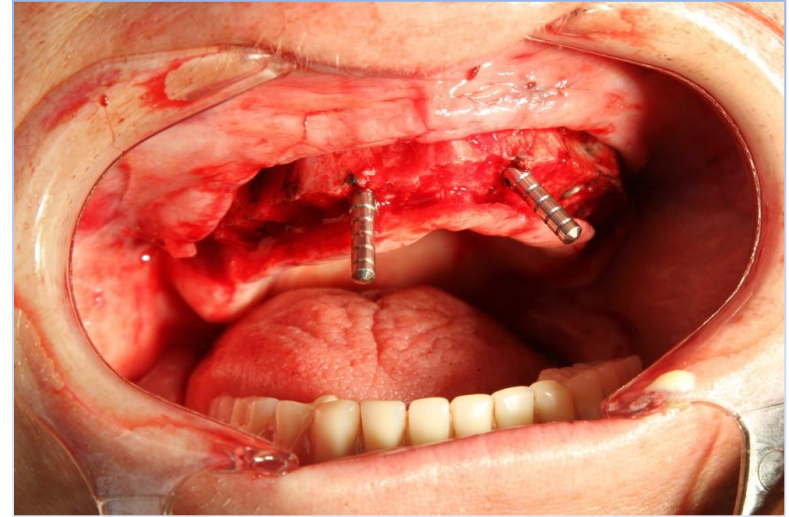



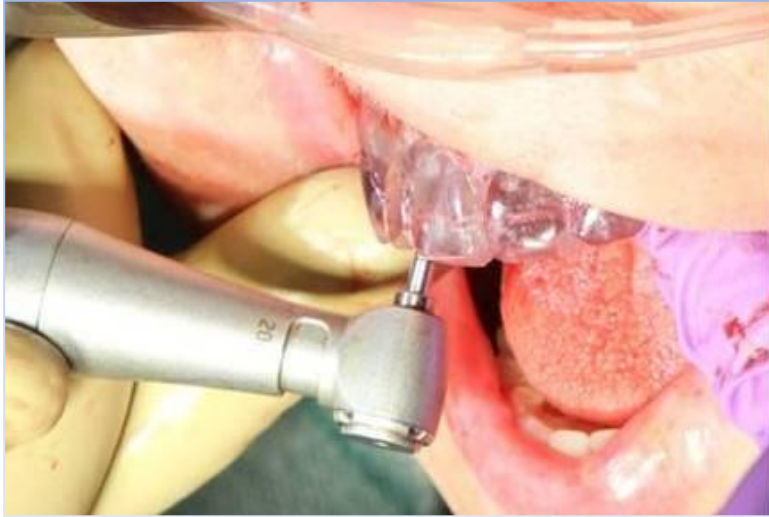
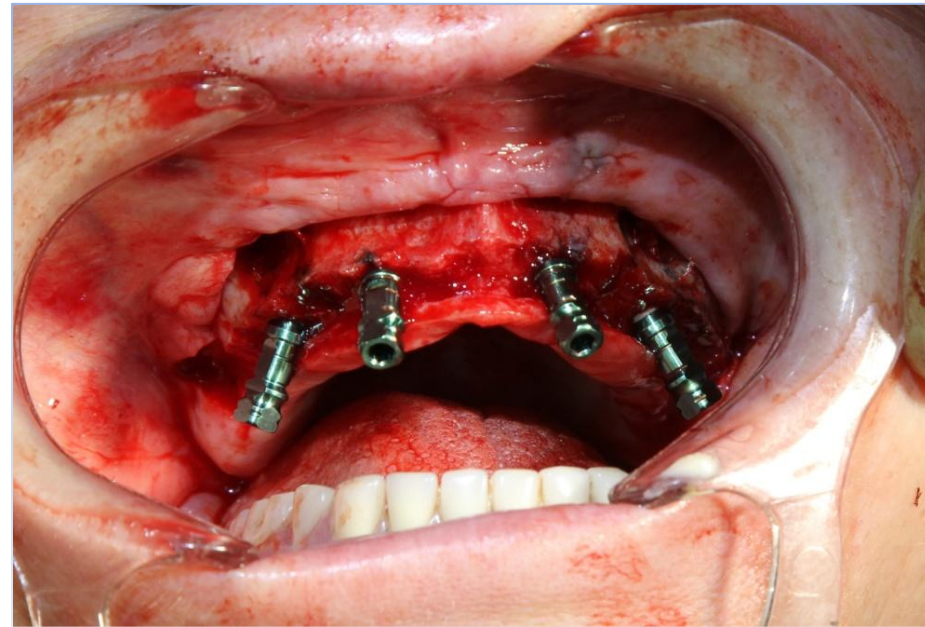
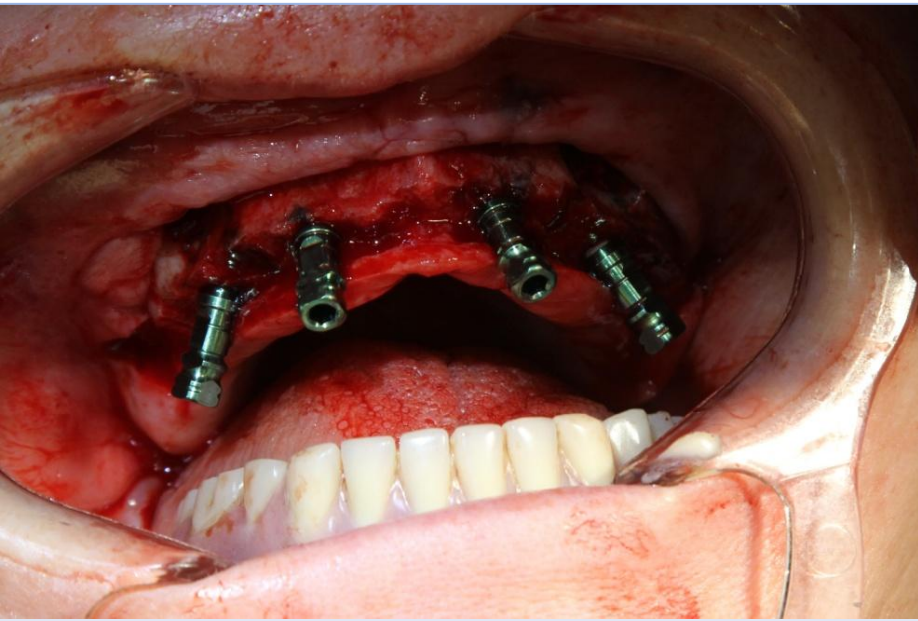


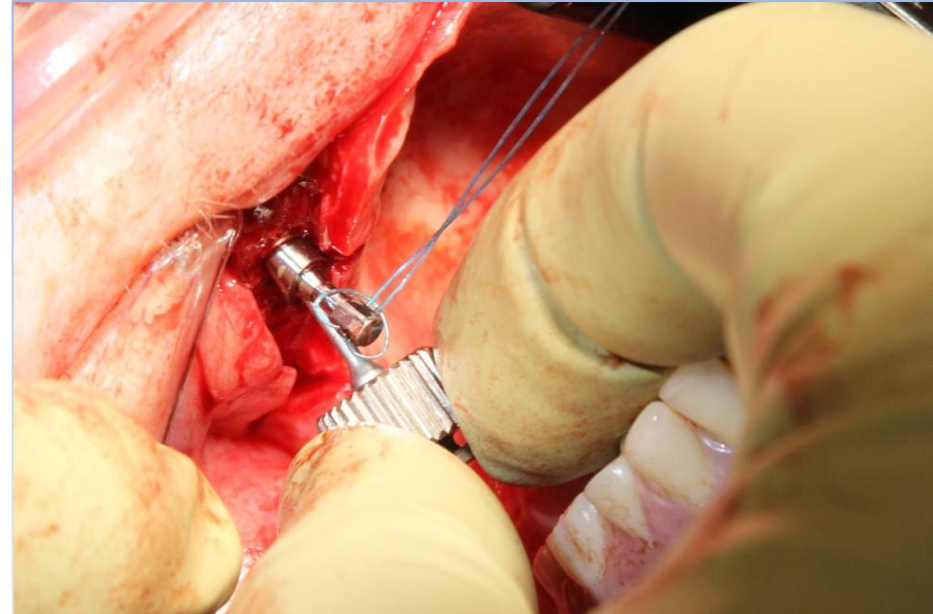
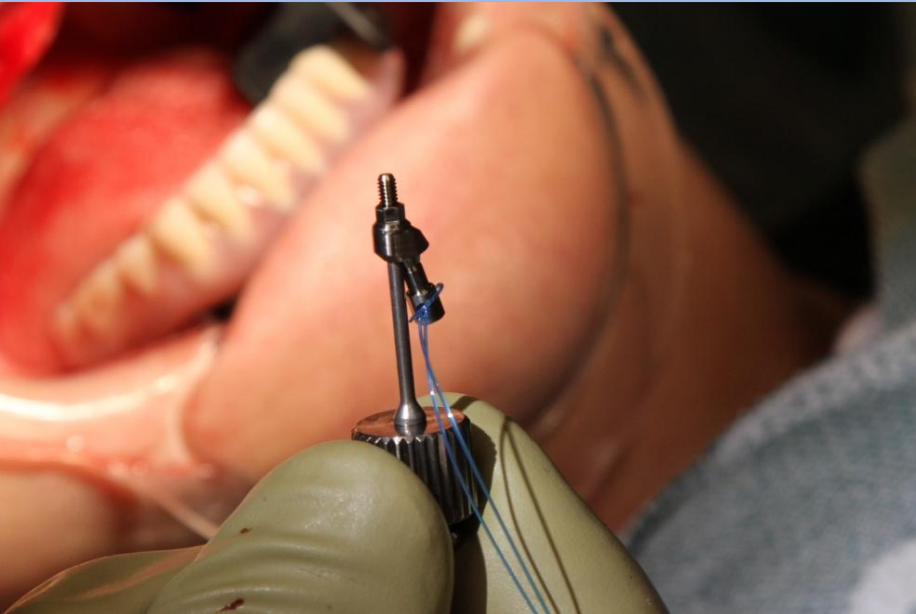




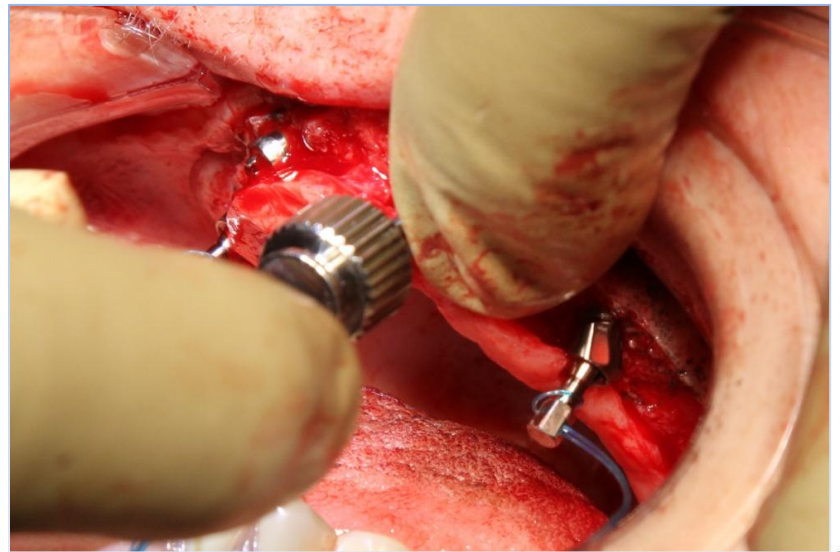
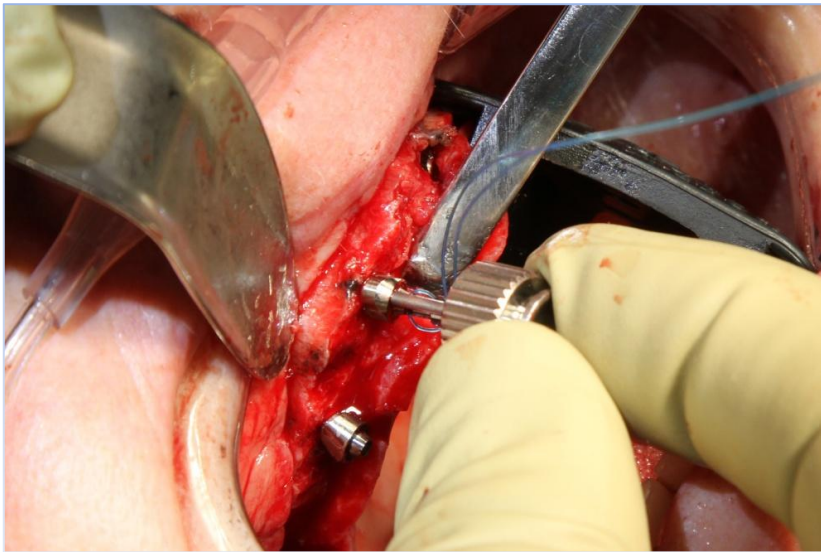
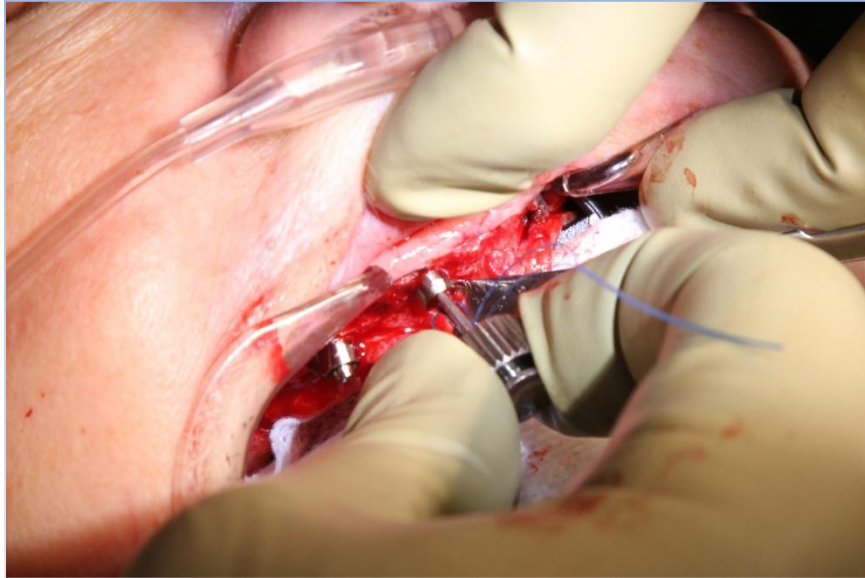




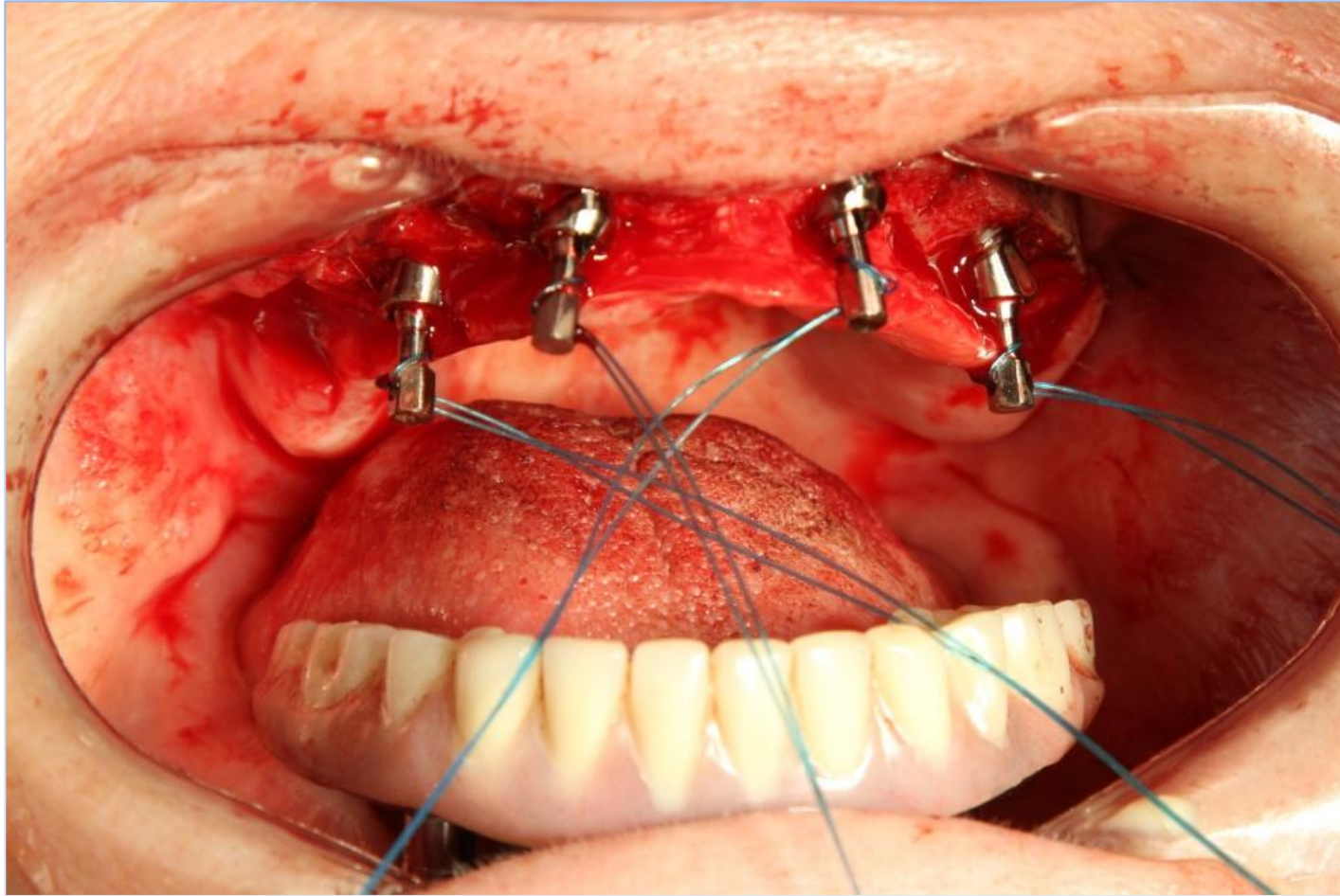


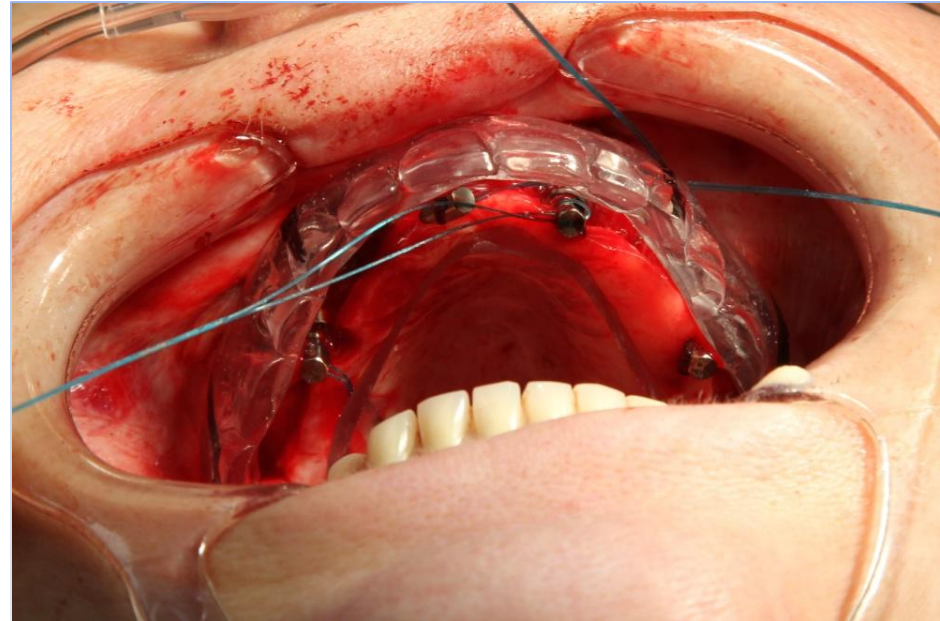
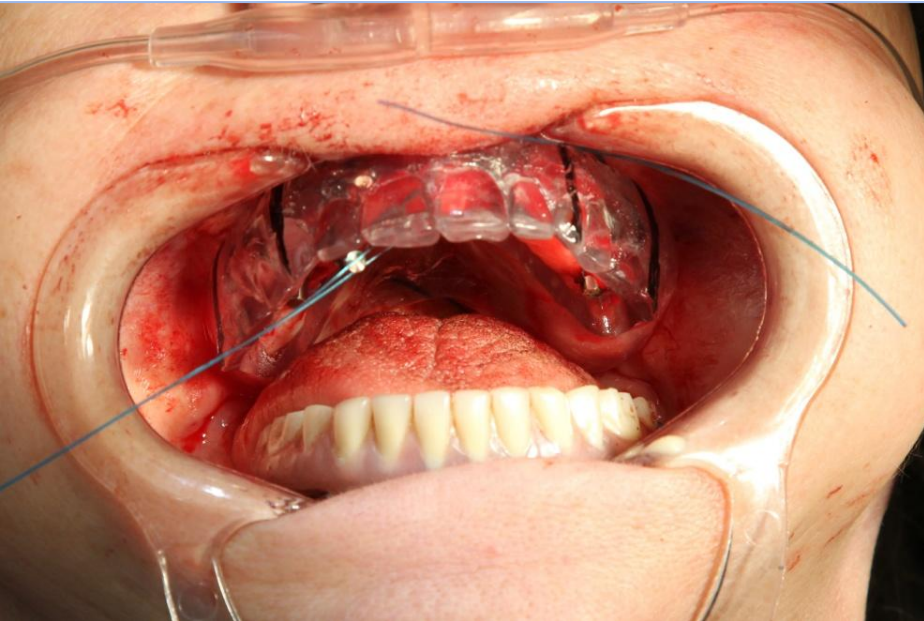




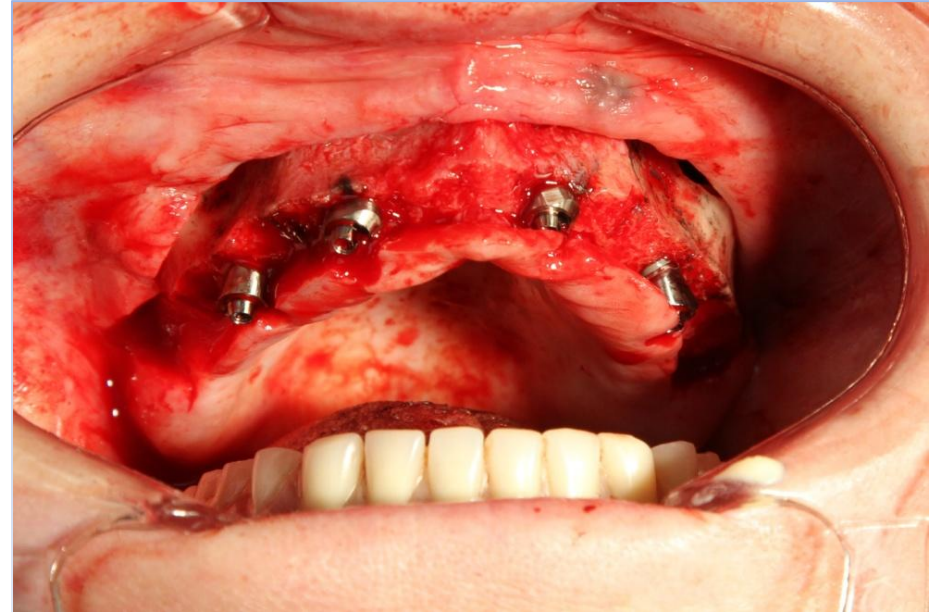
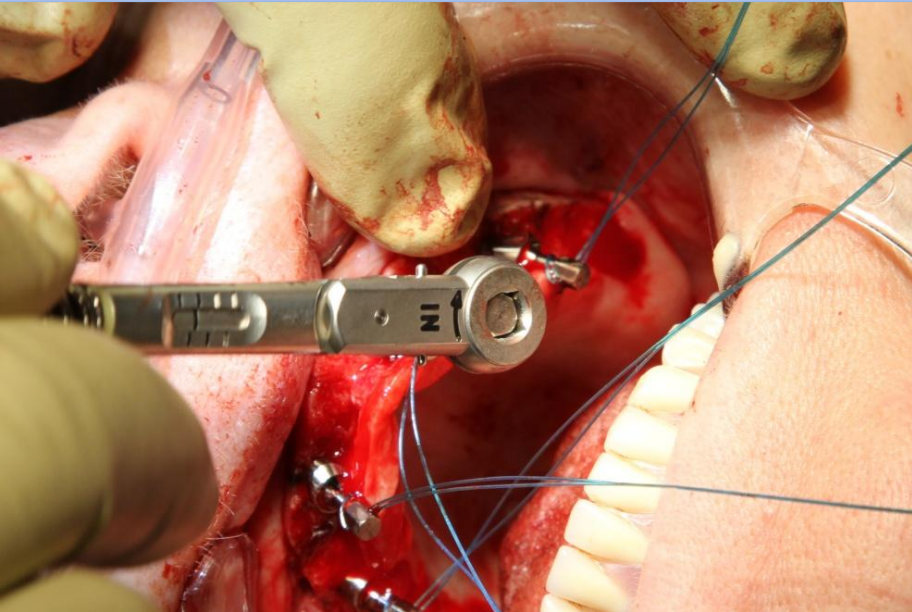




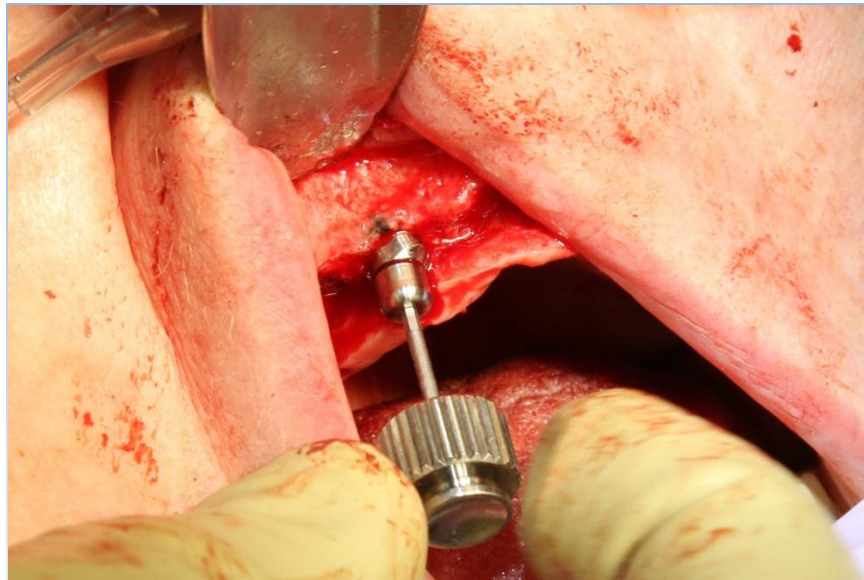
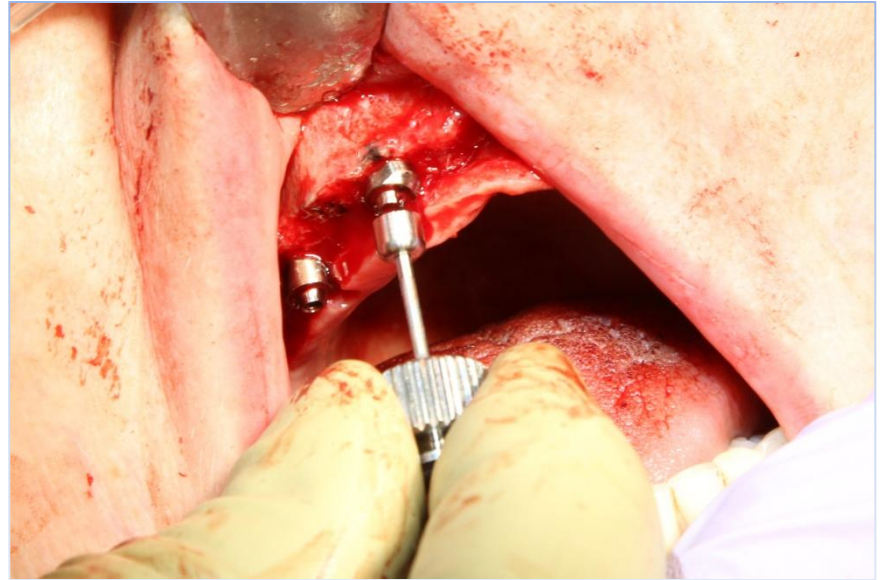



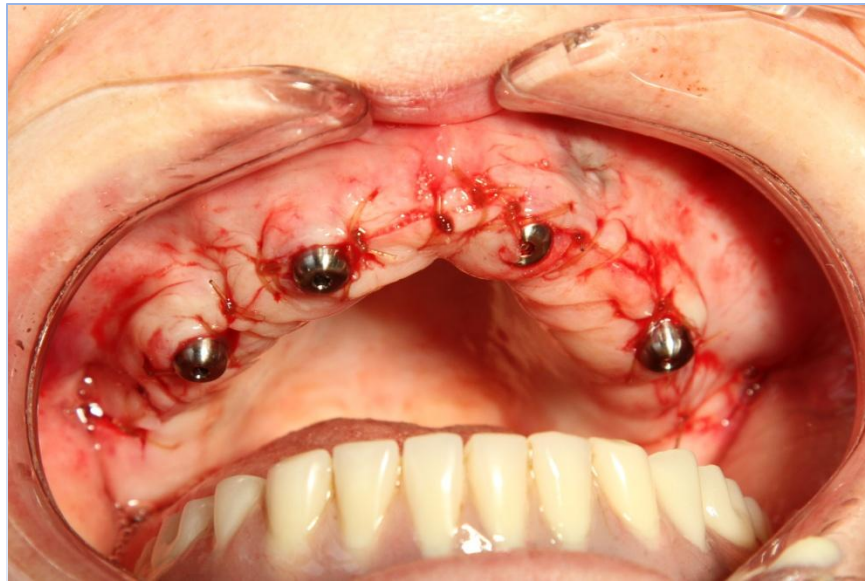
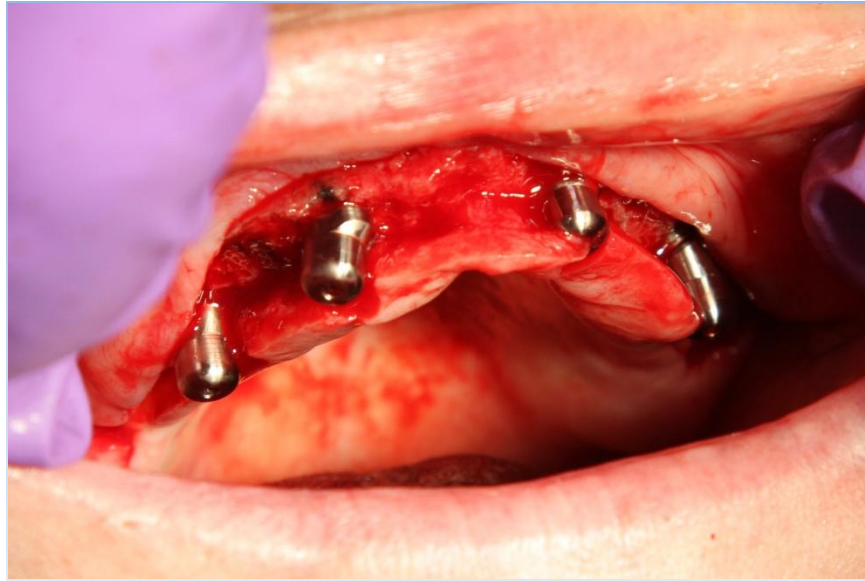





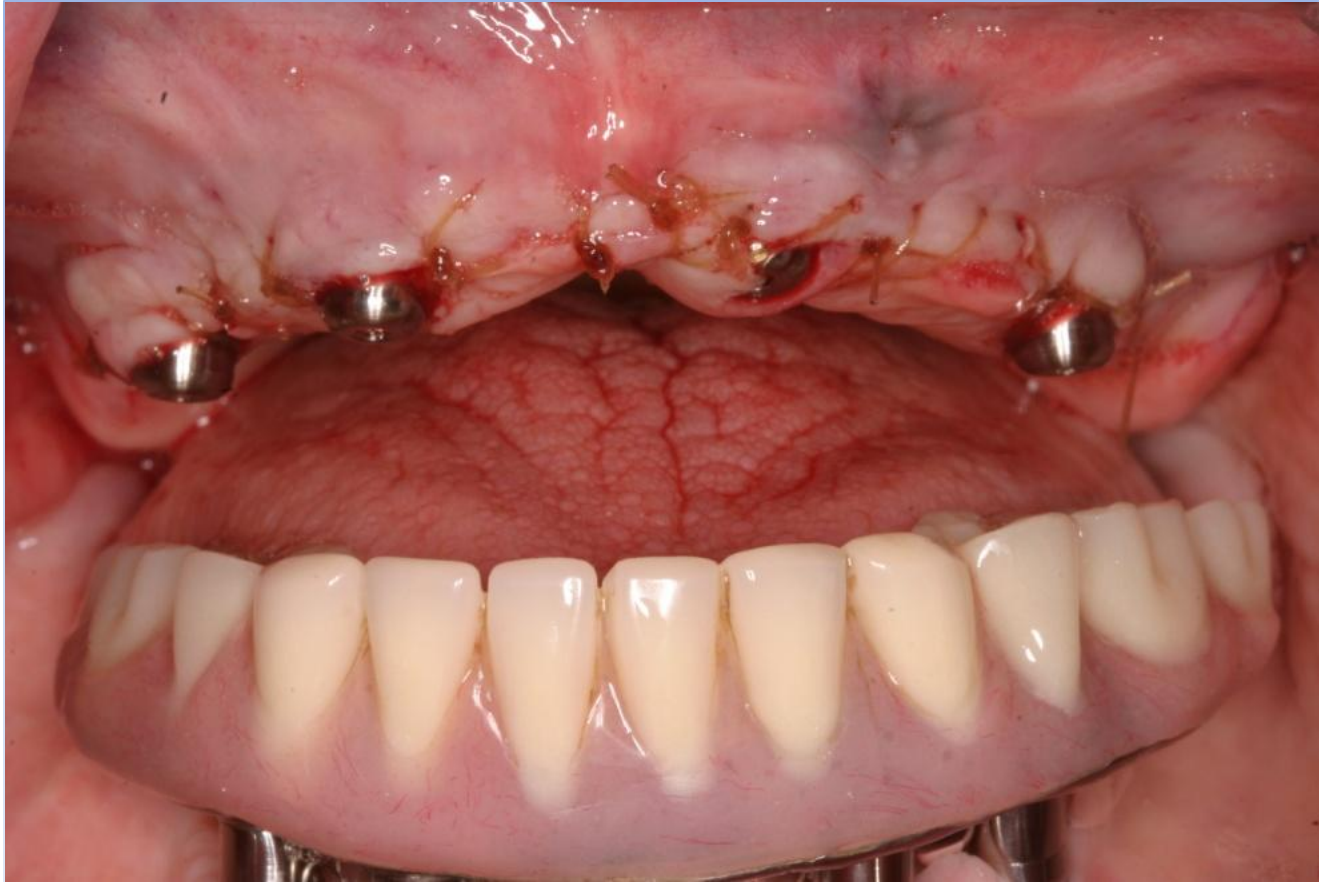
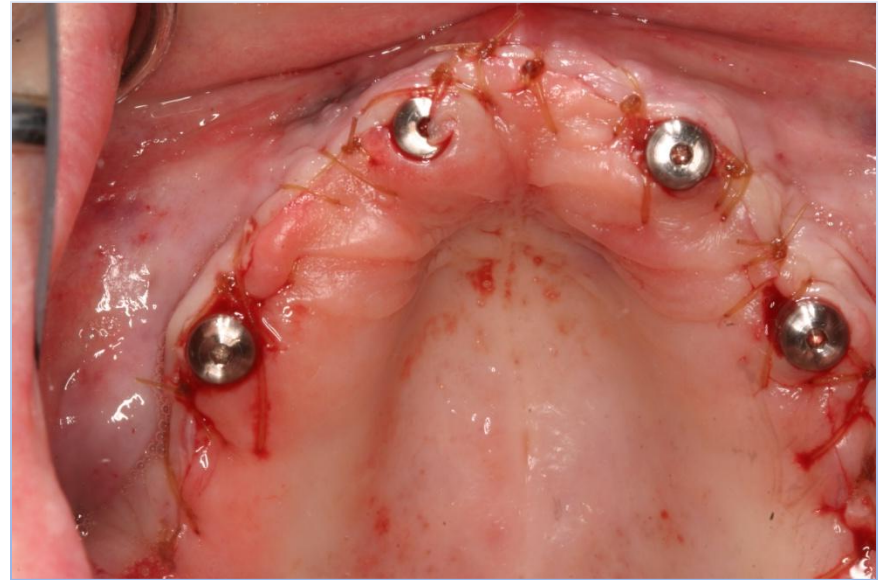


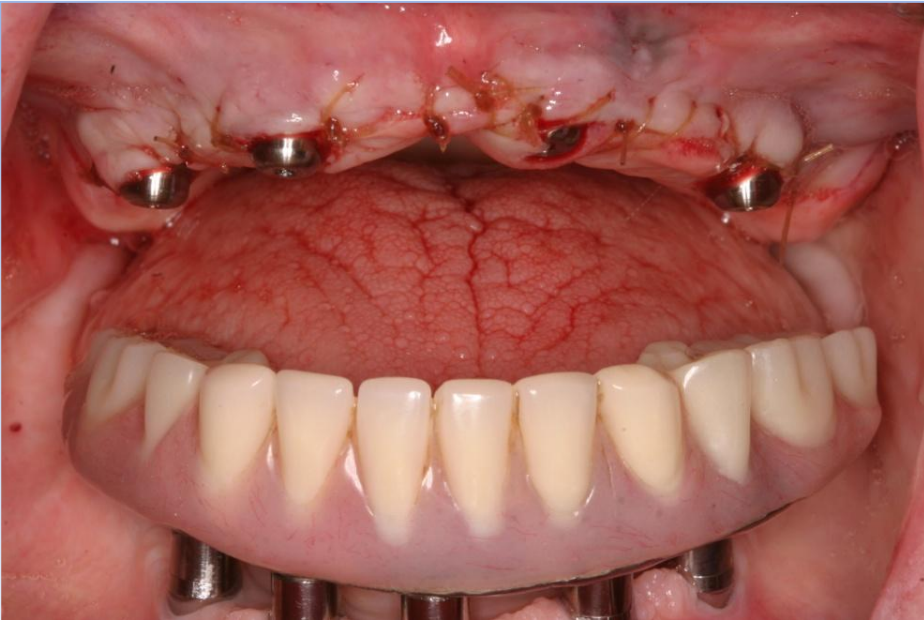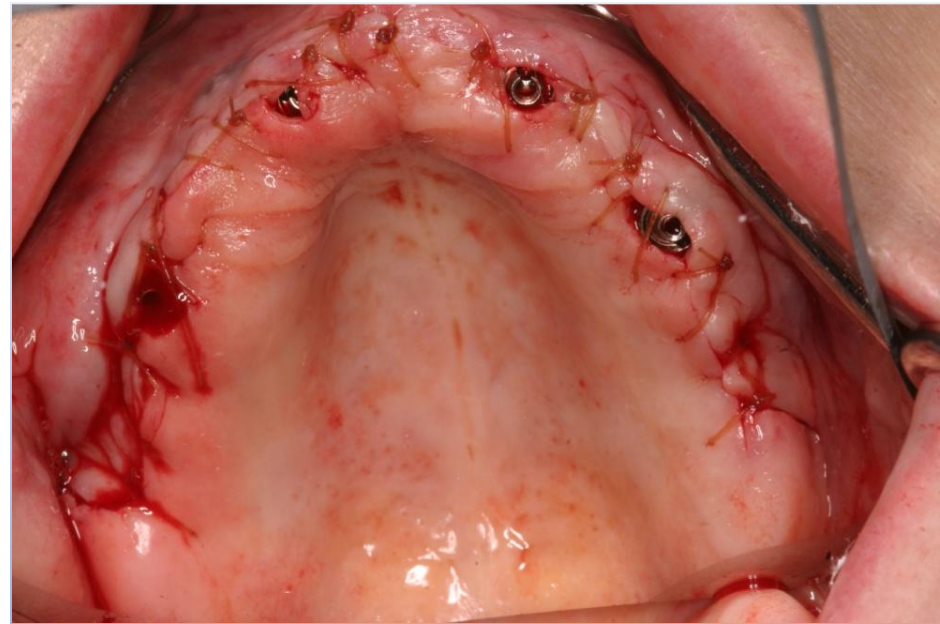
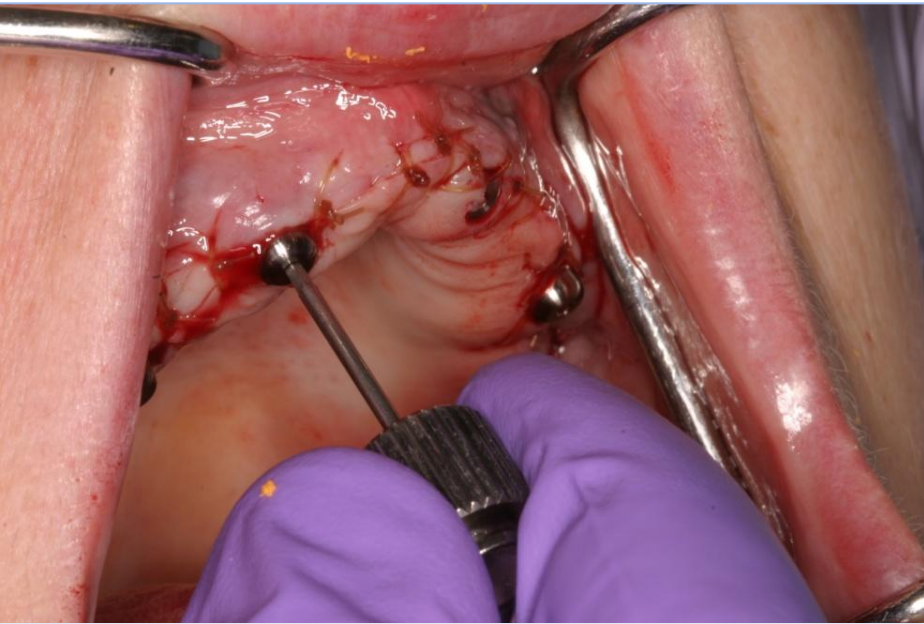




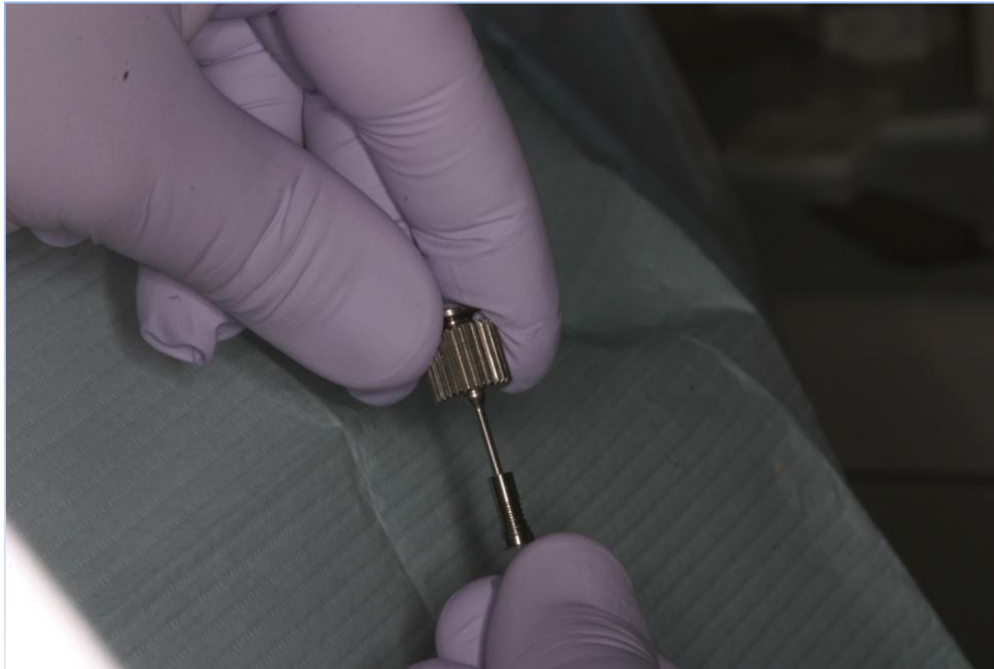






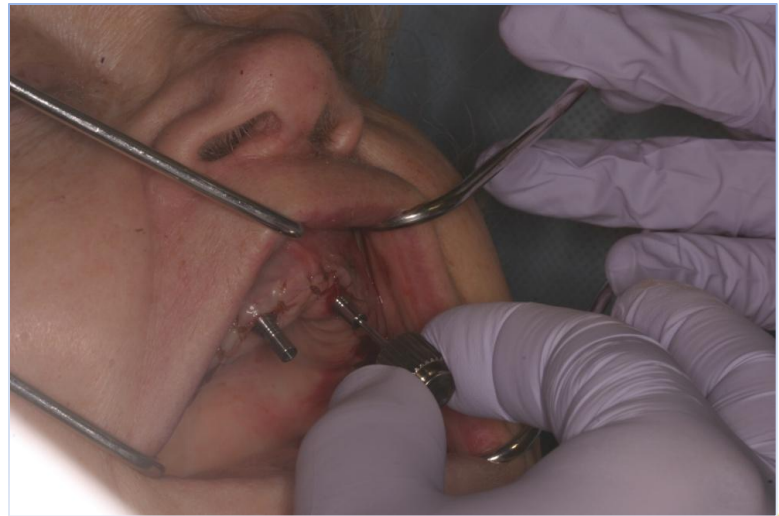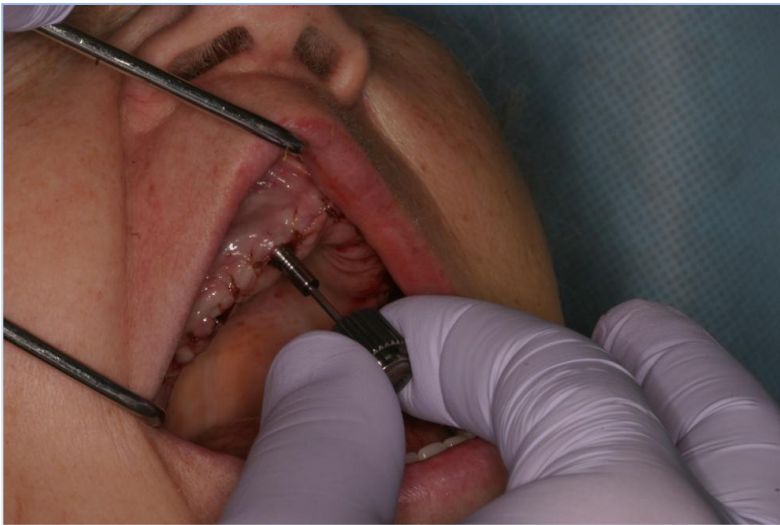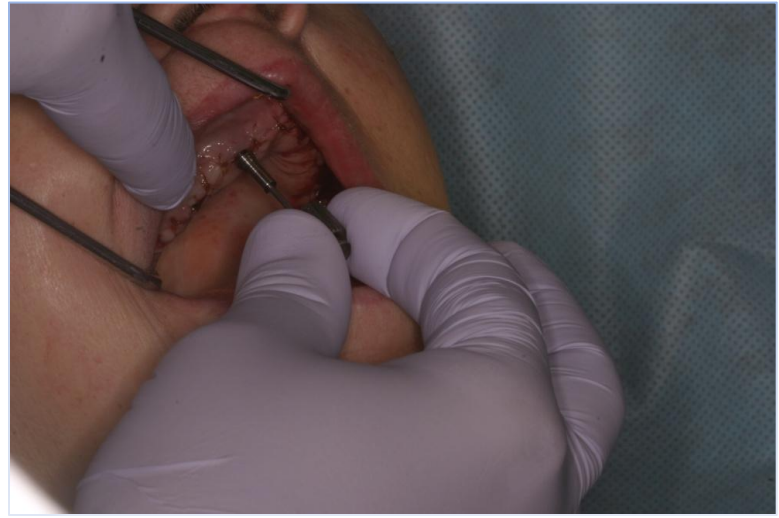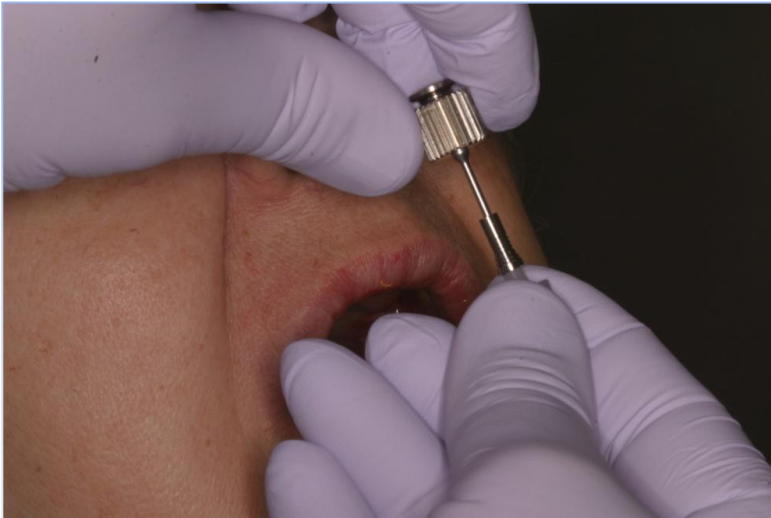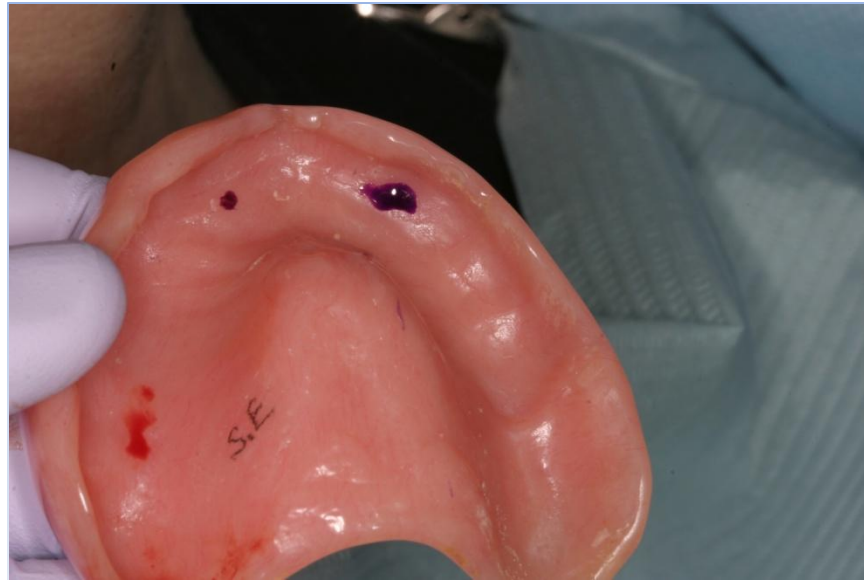
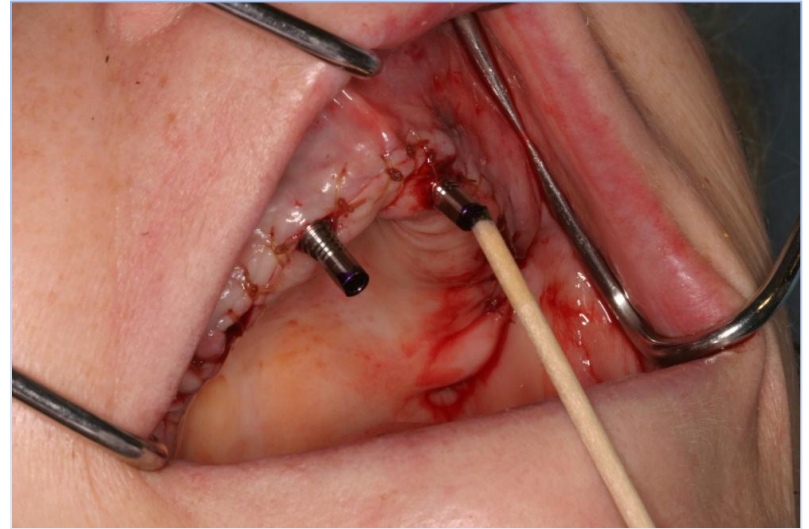
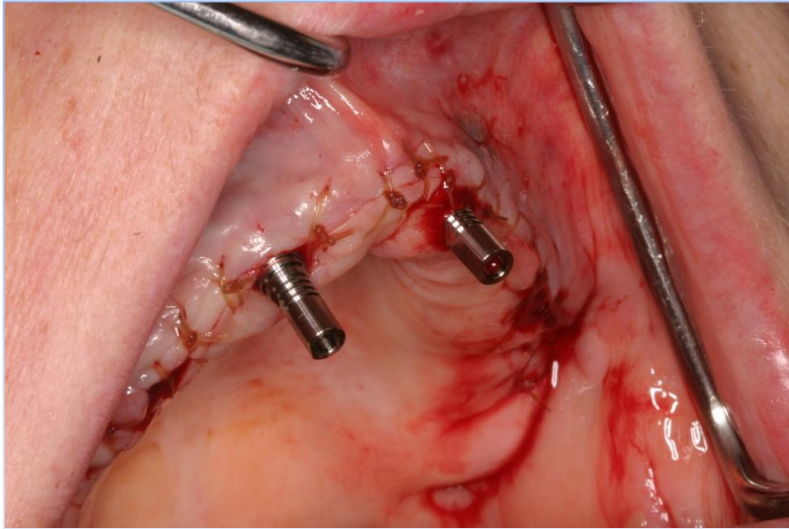











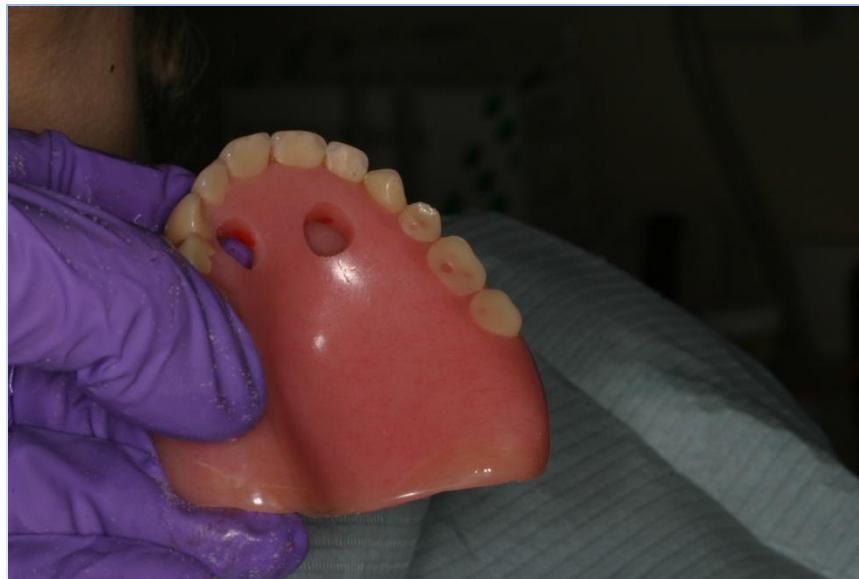
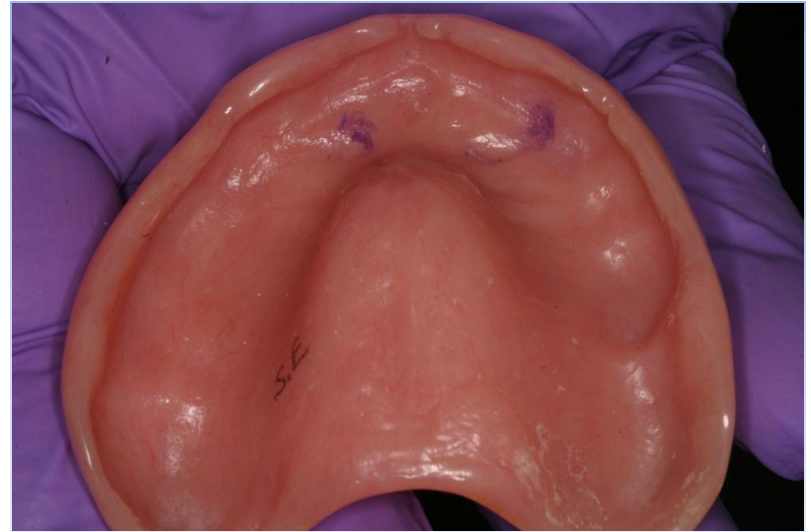
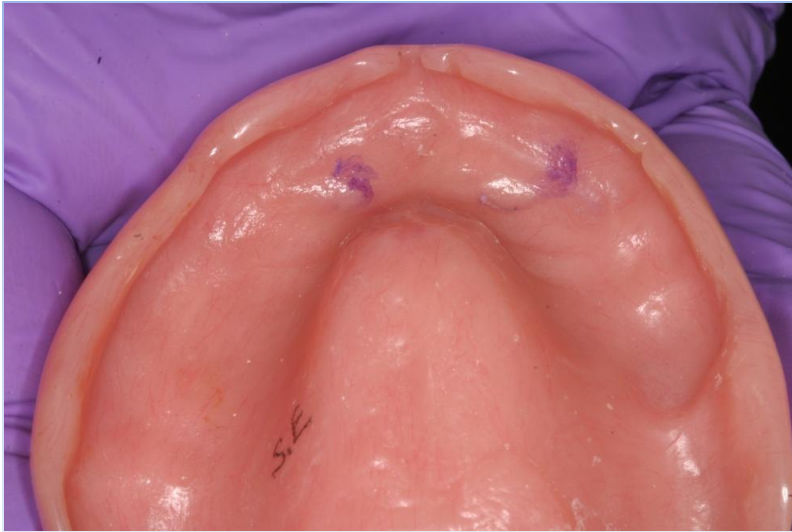
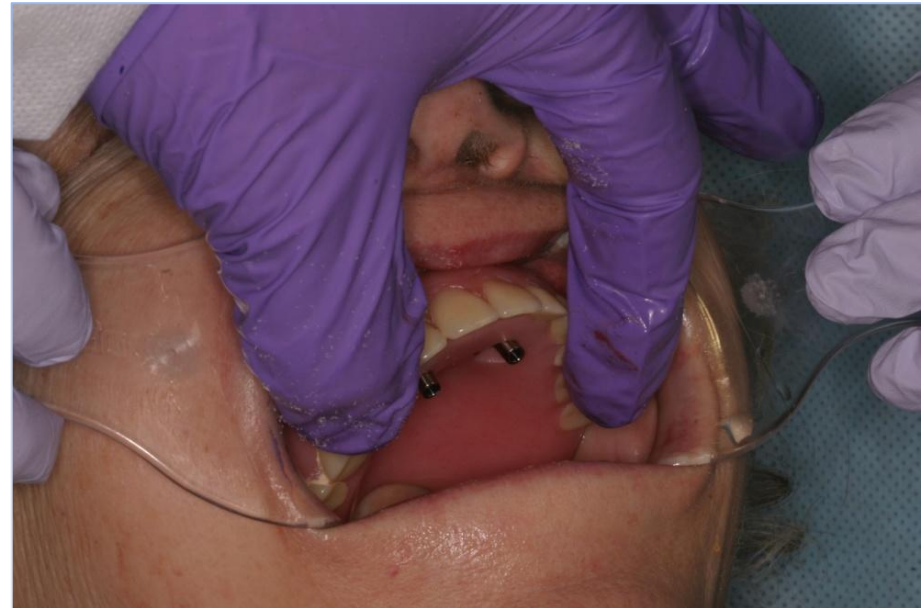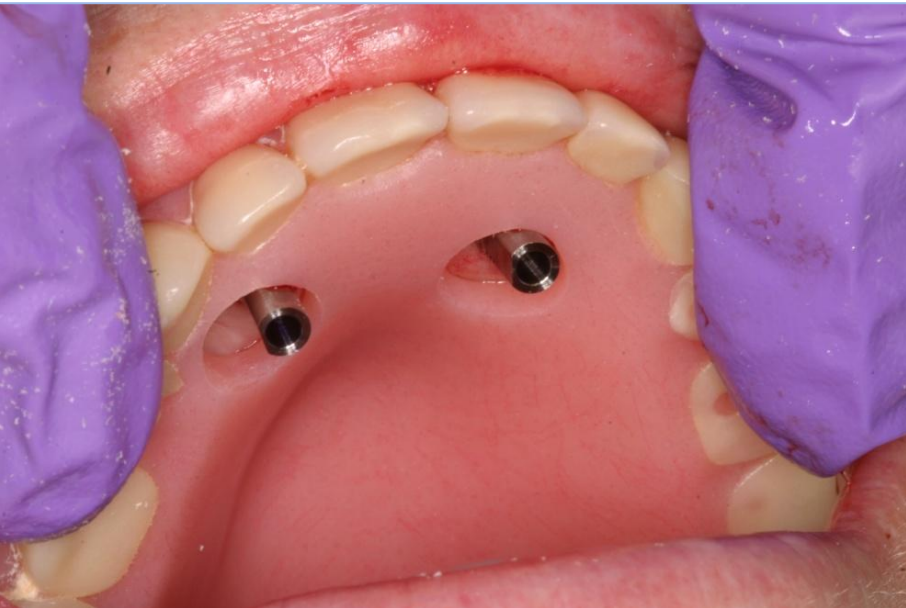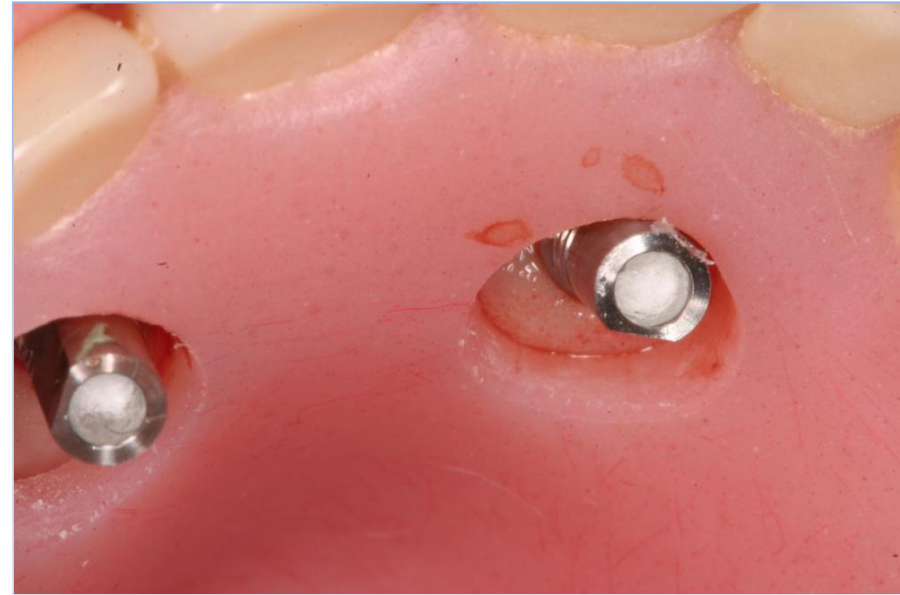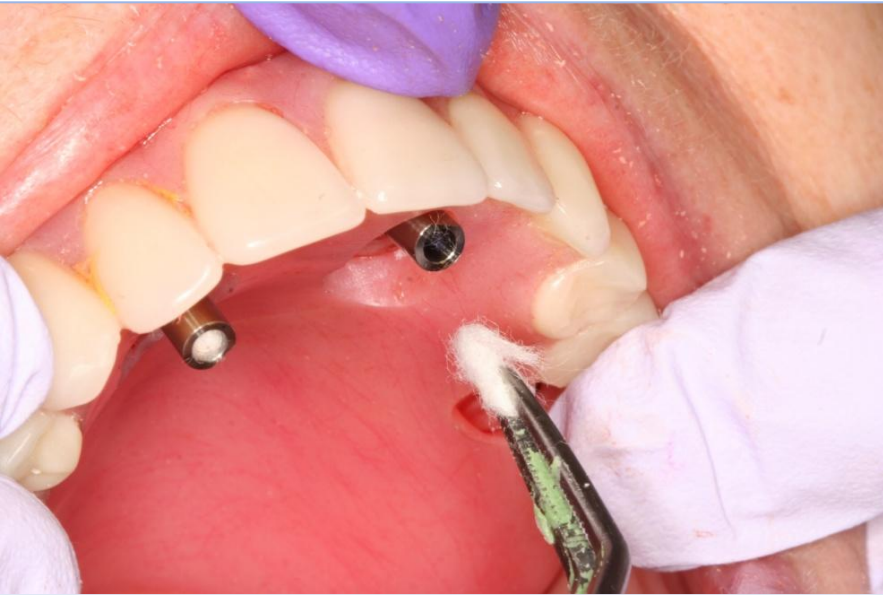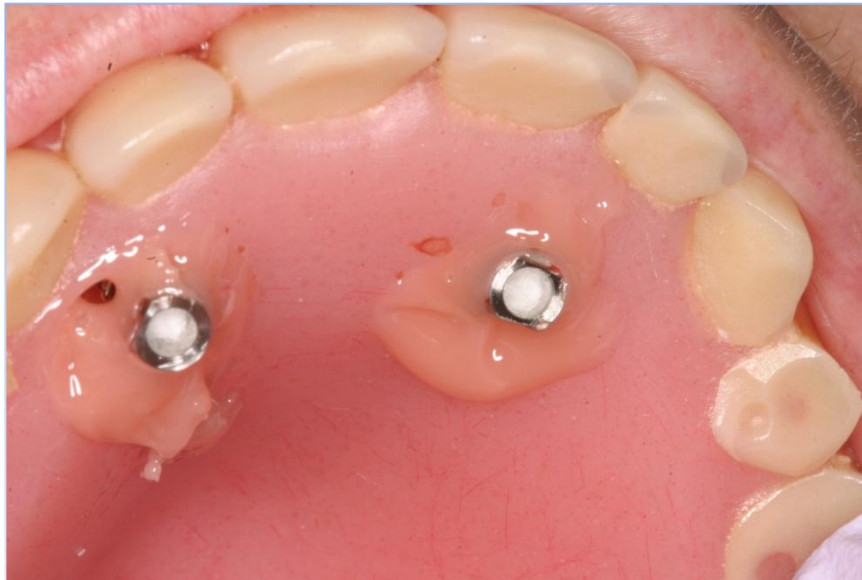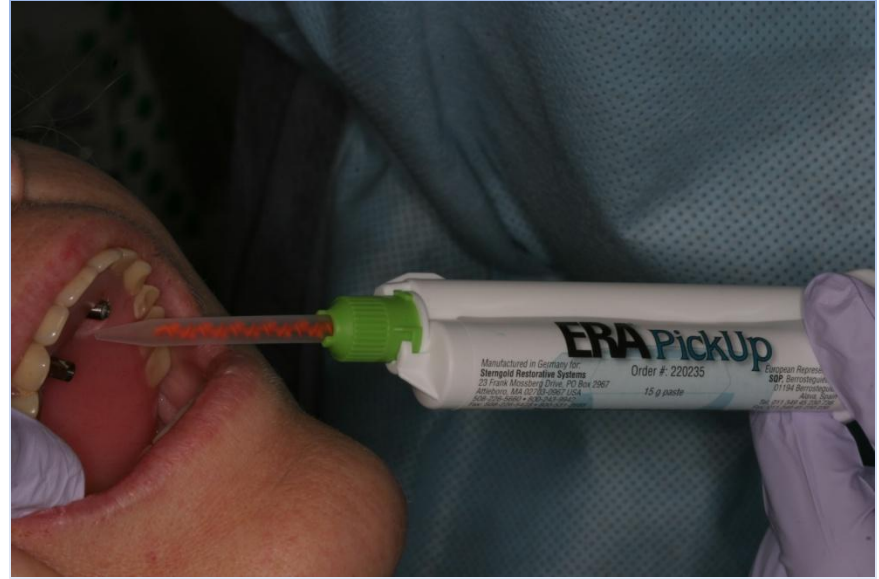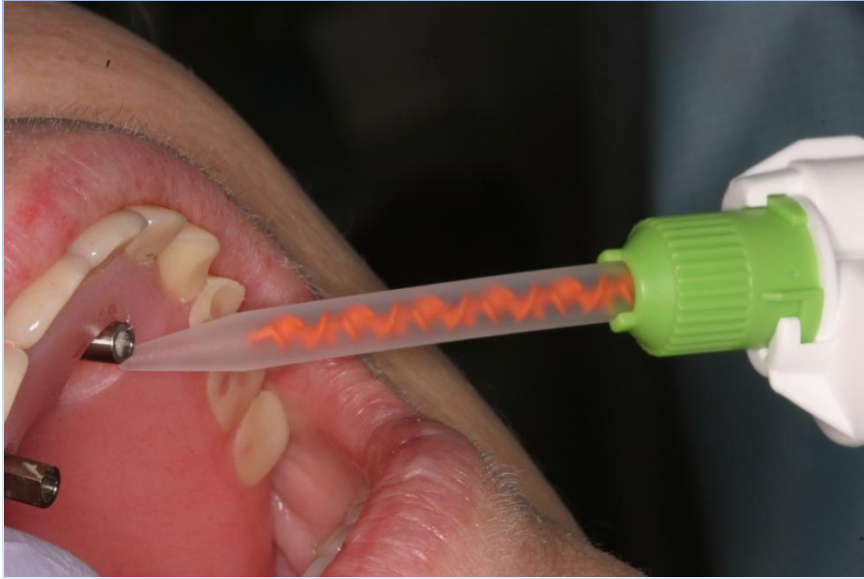part# 6555, rev 5/2012



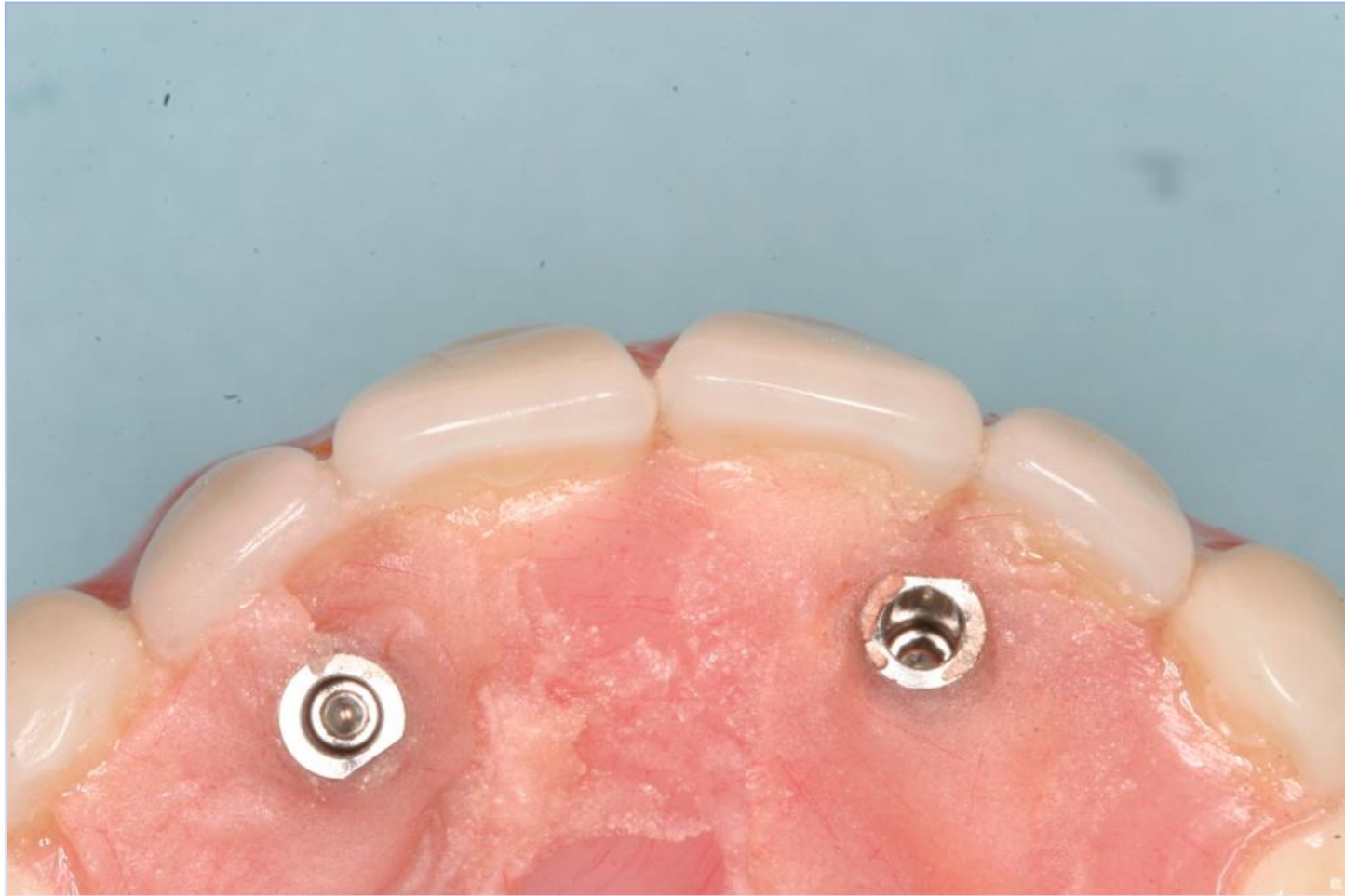




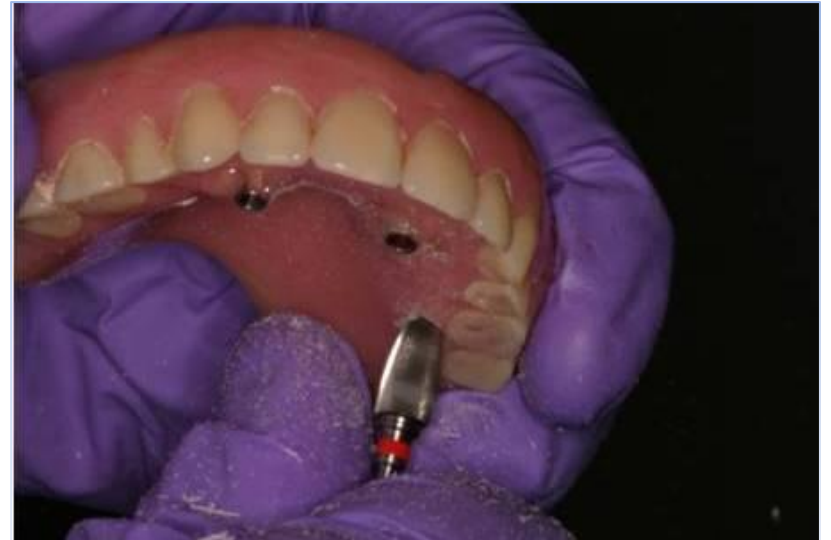
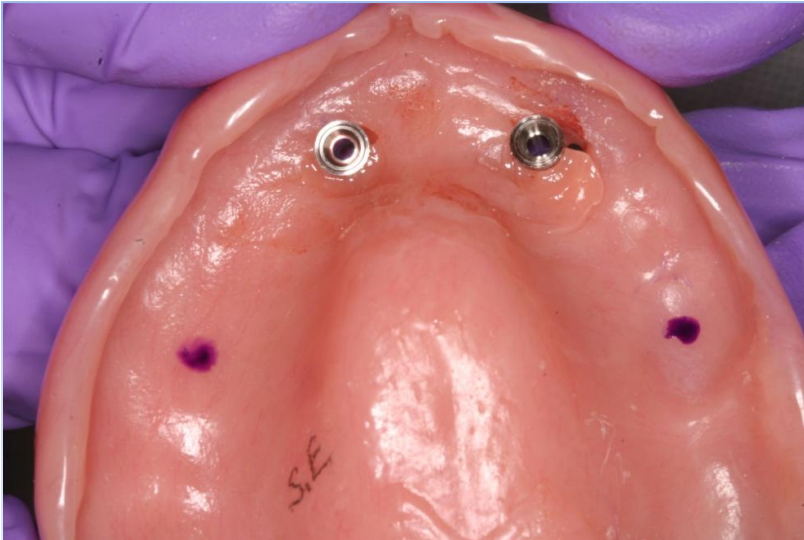
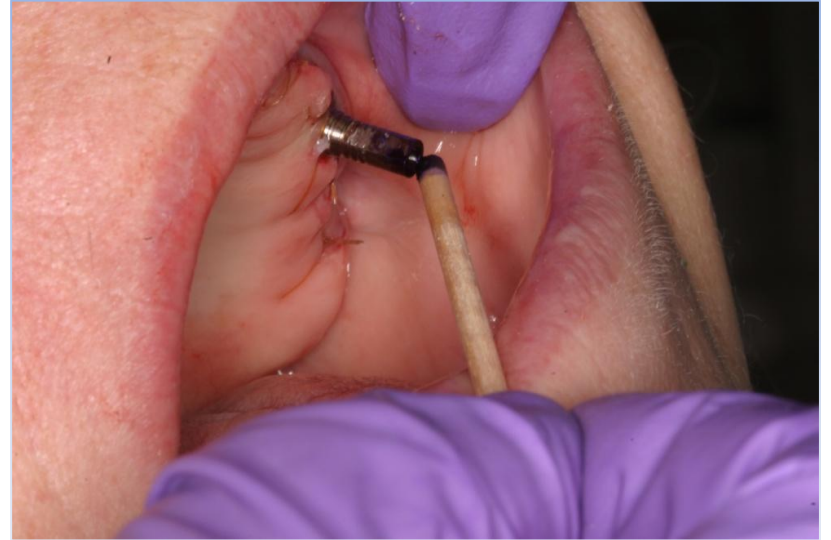
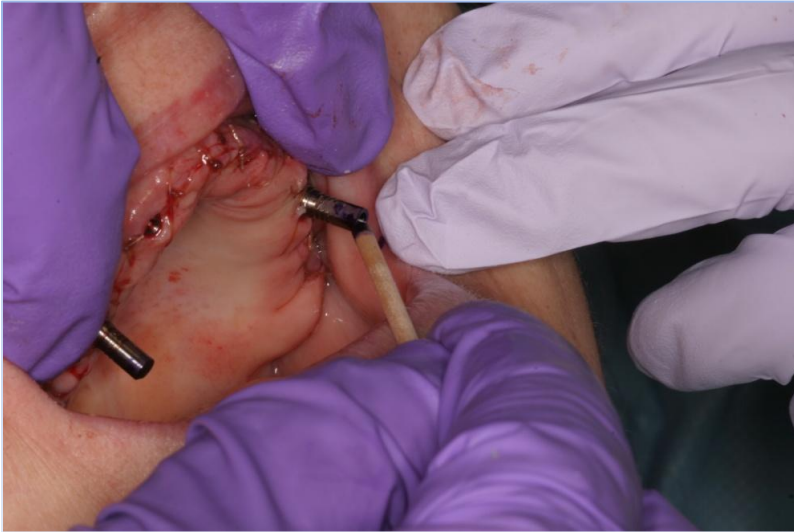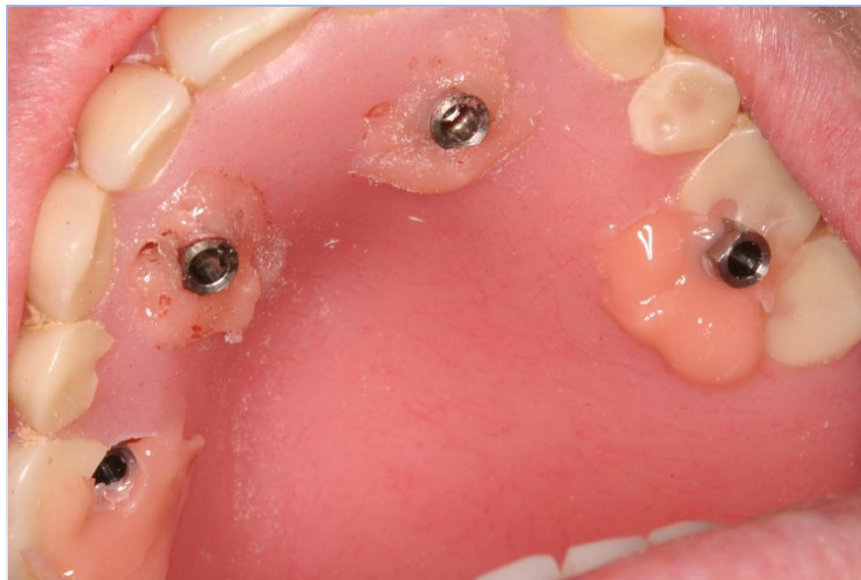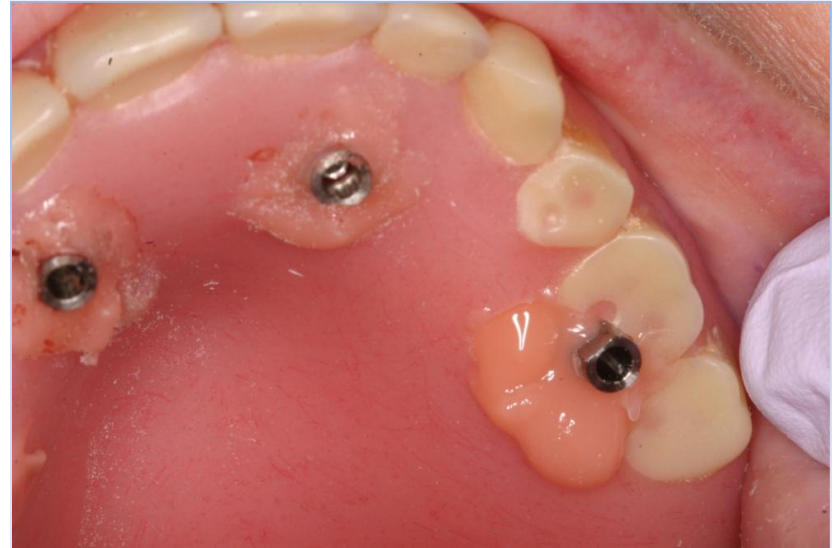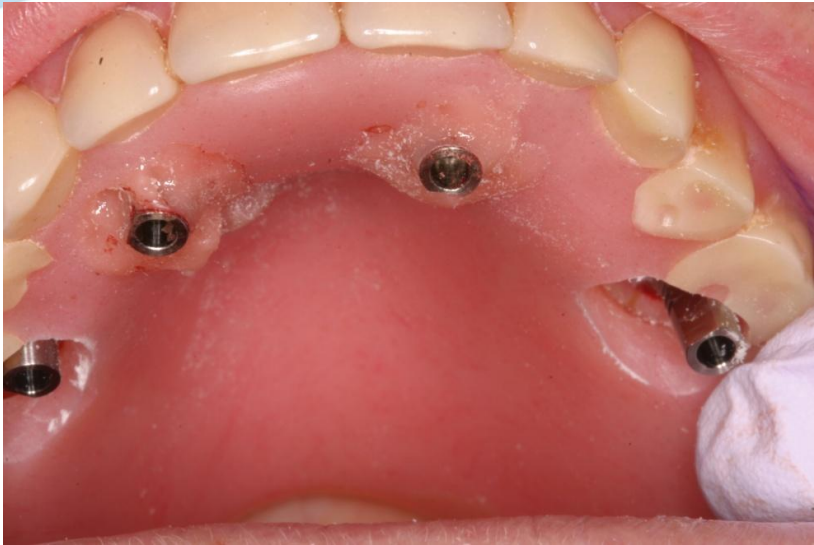part# 6555, rev 5/2012



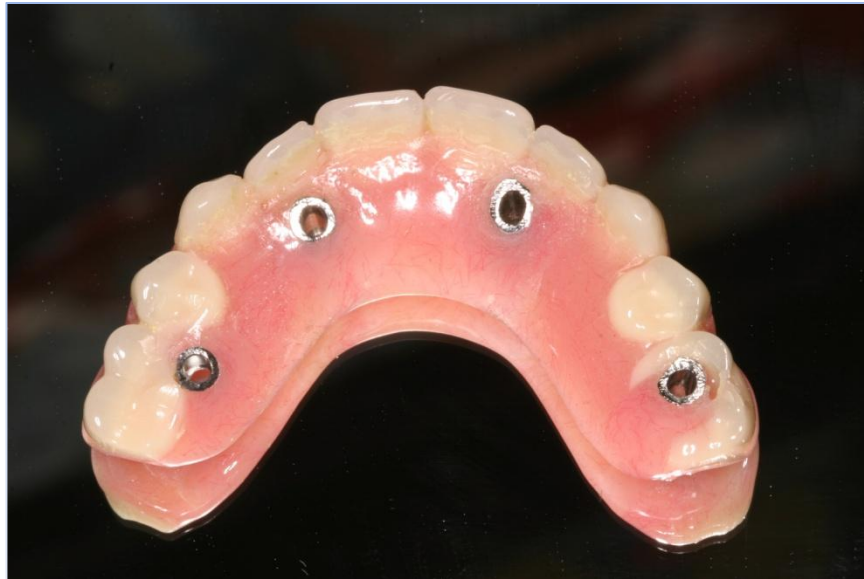
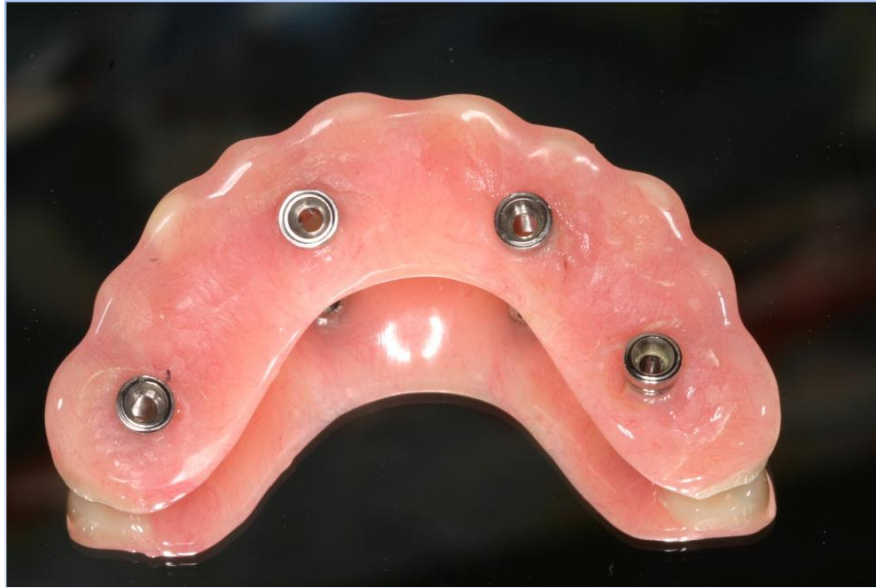
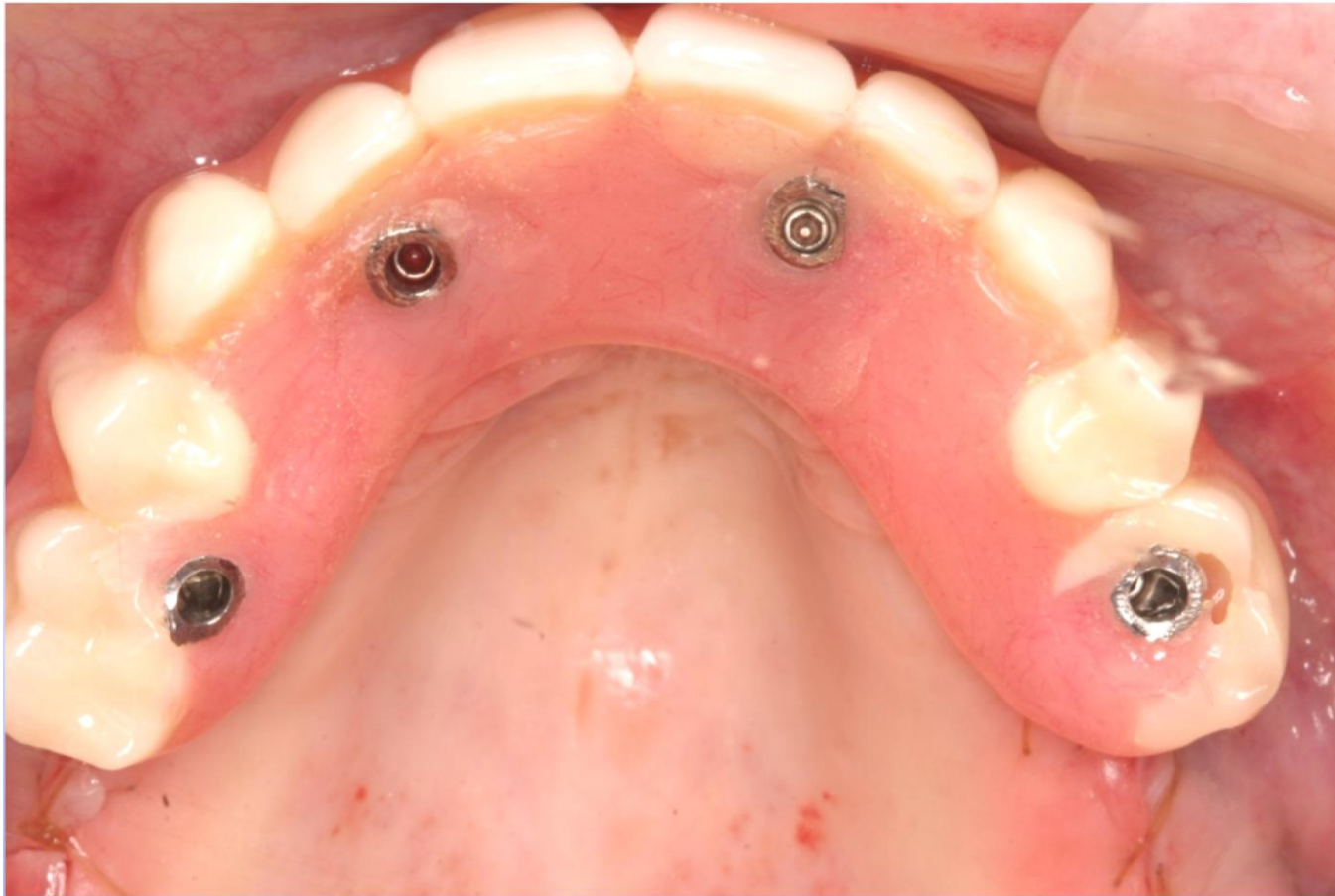




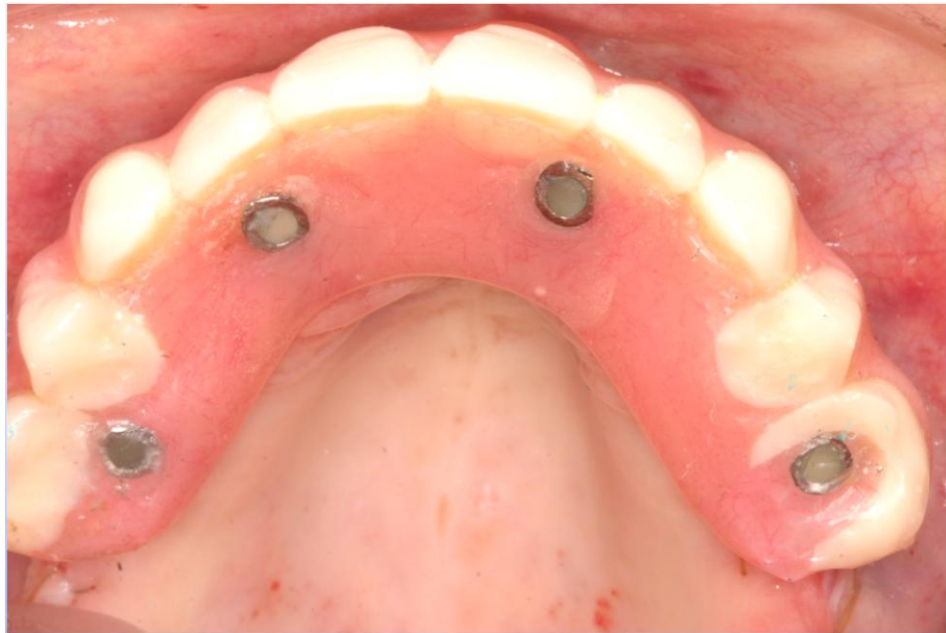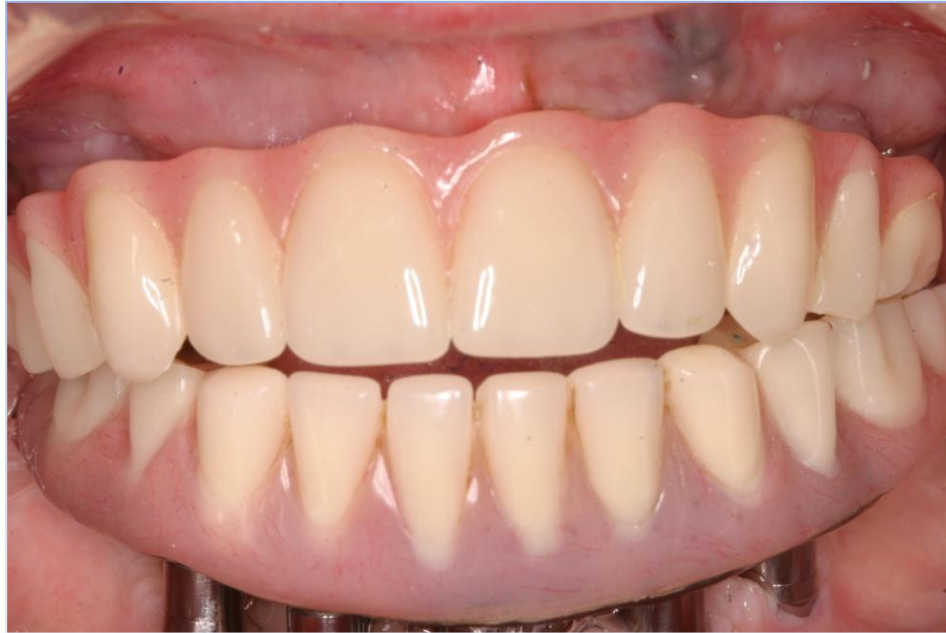part# 6555, rev 5/2012



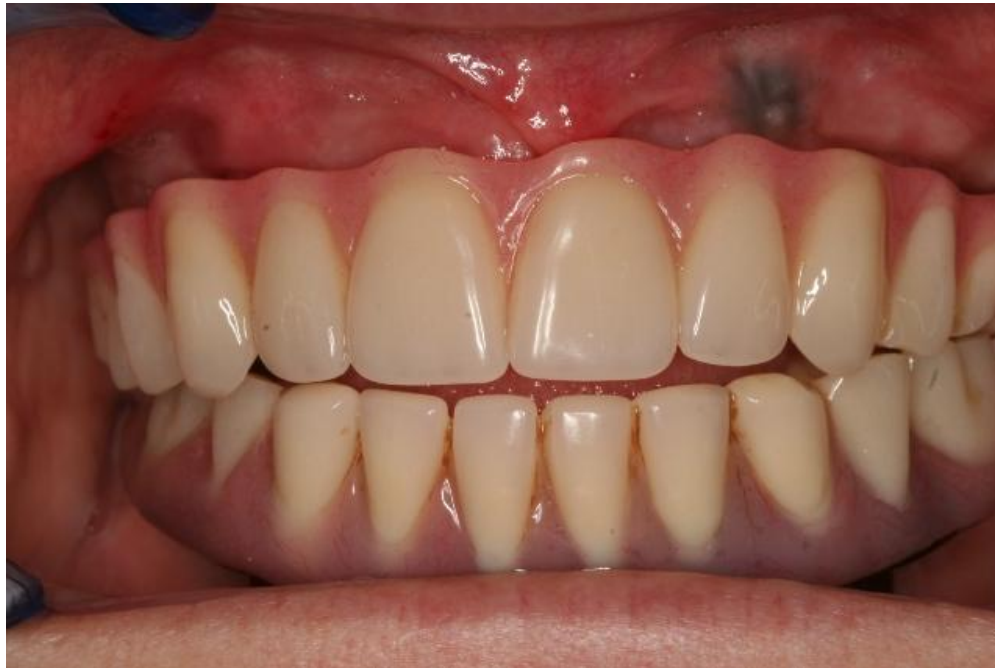
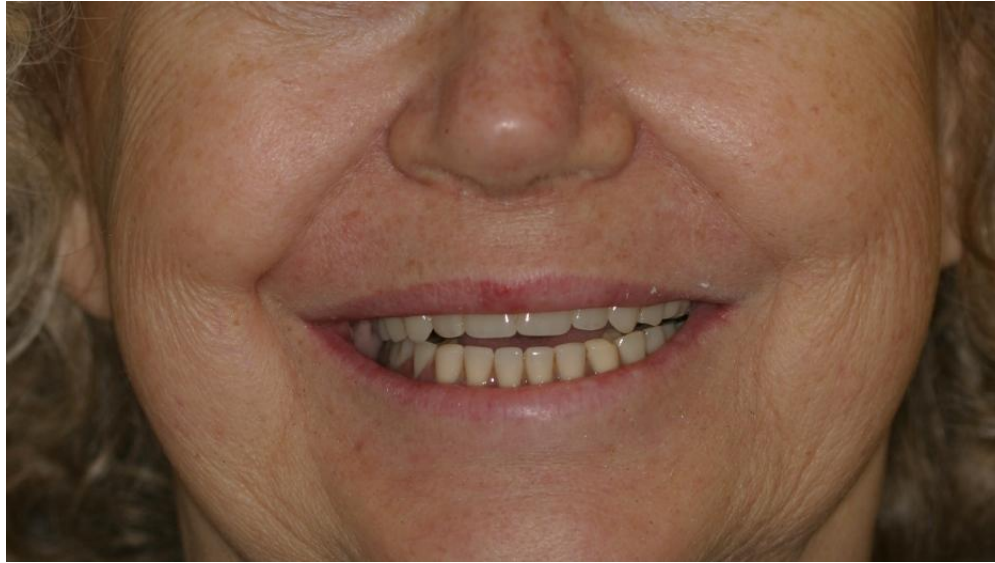


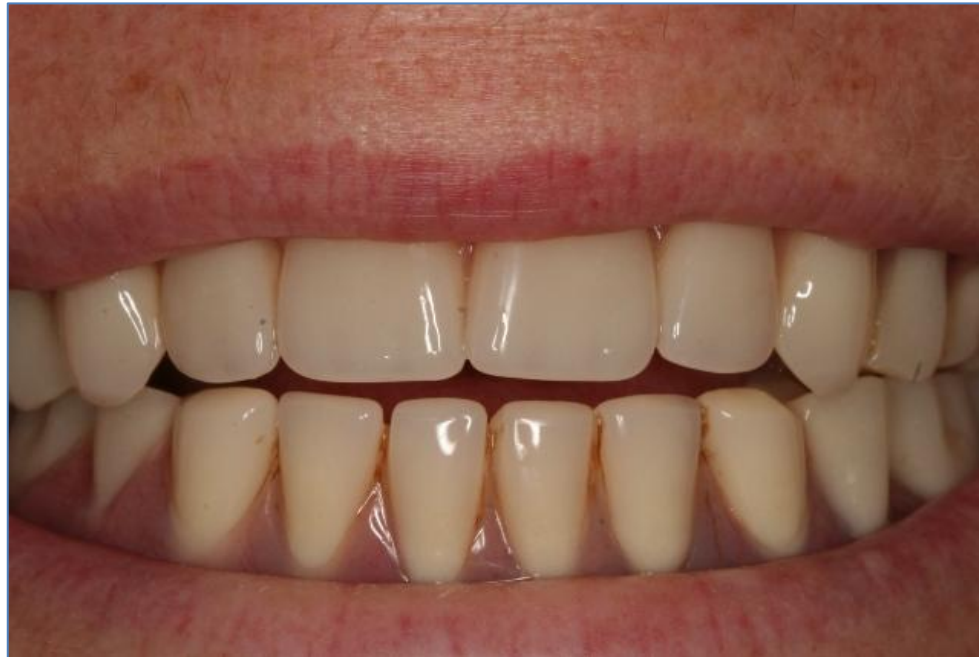
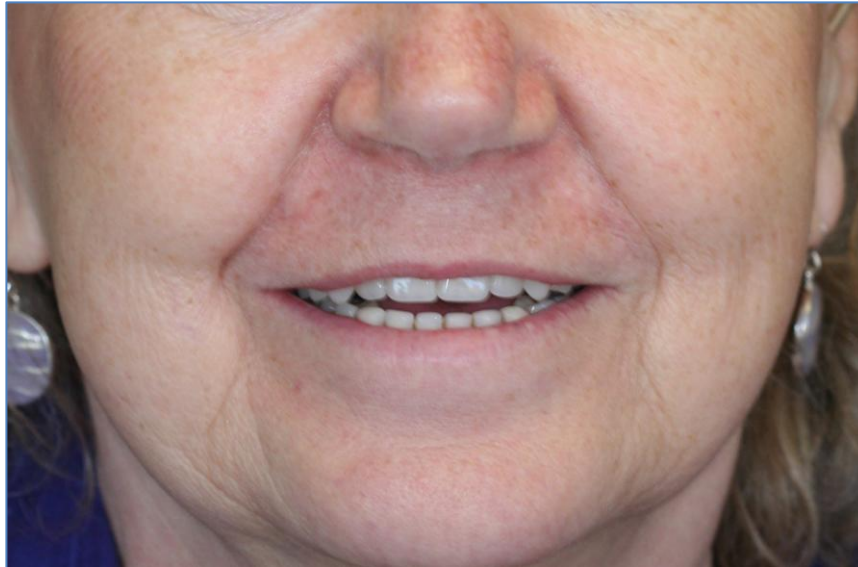
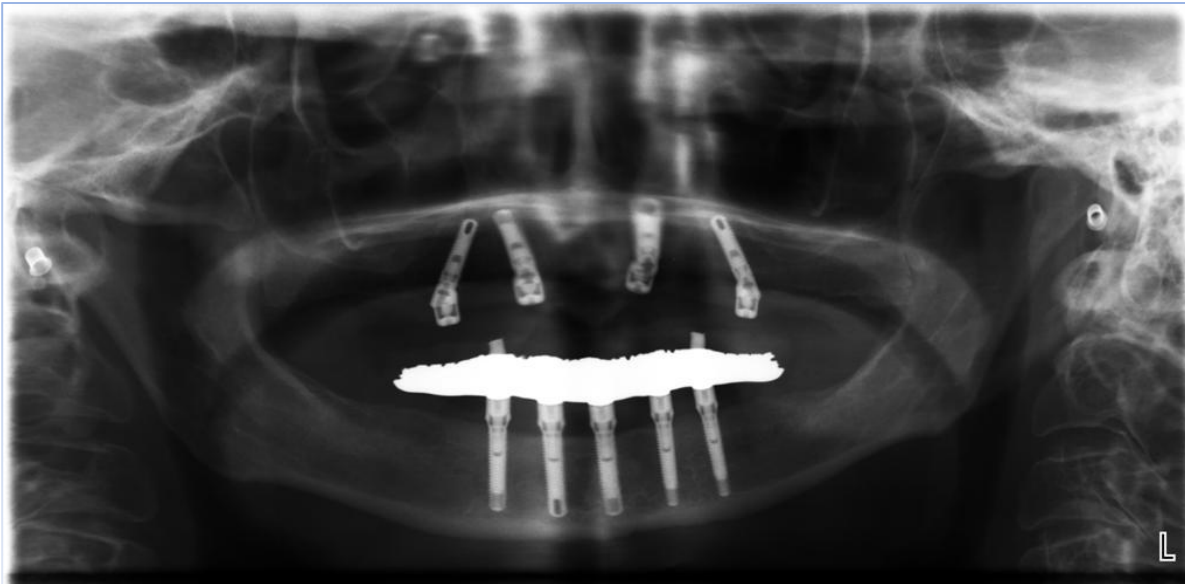
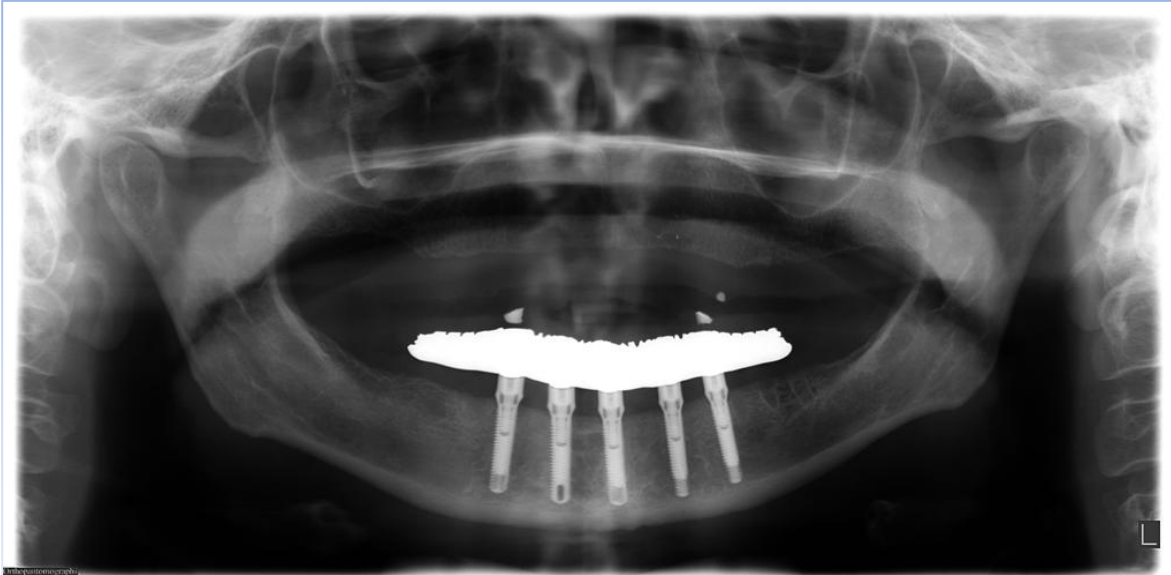


part# 6555, rev 5/2012









part# 6555, rev 5/2012

# Questions??

# The End